



Fibre Reinforced Composite-Fixed Partial Denture: A Case Series

Dr. Dhananjay Dhiren Sheth¹, Dr. Stuti Chandrajit Jha², Dr. Bhagyashree Kalsekar³, Dr. Ajay V. Sabane⁴, Dr. Paresh Gandhi⁵, Dr. Neel Doshi⁶

1. MDS, Prosthodontics and Crown and Bridge, Bharati Vidyapeeth Dental College and Hospital, Pune, Maharashtra, India
2. Assistant Professor, Department of Periodontology, Bharati Vidyapeeth Dental College and Hospital, Pune, Maharashtra, India
3. Post Graduate, Department of Periodontology, Bharati Vidyapeeth Dental College and Hospital, Pune, Maharashtra, India
4. Lecturer, Department of Prosthodontics and Crown and Bridge, Bharati Vidyapeeth Dental College and Hospital, Pune, Maharashtra, India
5. Professor and Head of The Department, Department of Prosthodontics and Crown and Bridge, Bharati Vidyapeeth Dental College and Hospital, Pune, Maharashtra, India
6. Professor, Department of Prosthodontics and Crown and Bridge, Bharati Vidyapeeth Dental College and Hospital, Pune, Maharashtra, India
7. Postgraduate, Department of Endodontics, Bharati Vidyapeeth Dental College and Hospital, Pune, Maharashtra, India.

(Received: 07 September 2023

Revised: 12 October 2023

Accepted: 06 November 2023)

KEYWORDS

Abstract:

In most societies, lack of anterior teeth is a serious problem in a patient's social life. While traditional removable partial dentures and implant support restorations are often the treatment of choice, fiber reinforced composite (FRCs) are a conservative, fast and cost-effective alternative for single and multiple tooth replacement.

BACKGROUND:

Loss of anterior teeth is a common form of injury, especially in children and adolescents. On the other hand, elderly people who maintain their teeth for a long period of time often develop tooth decay and periodontal disease, leading to tooth extraction. Patients with lost anterior teeth need immediate attention for restoration for aesthetic and functional reasons. With increasing patient demand for tissue preservation and aesthetics, and the desire to reduce treatment costs, dentists are making minimally invasive and chairside (direct) dental prostheses with fixed removable partial dentures (FPDs)^{1,2}. We are looking for materials and technologies that enable us. In recent years, the development of fiber reinforced composite (FRP) has allowed dentists to produce resin-bonded, aesthetically pleasing, metal-free tooth restorations for single and multiple tooth replacements. FRC Fixed Partial Dentures (FPDs) are an alternative to composite-bonded FPDs for metal frames and may be alternatives to full-surface crown support FPDs and implant support crowns.^{3,4} FRC, made of fiberglass, is the only currently accepted cosmetic material that can be treated intraoral to form a bridge frame, while firmly adhering to the remaining dentin and achieving strength. Definitely suitable for human bite

function. Many studies have focused on improvement of FRC FPD's strength^{5,6}. The most accepted concept for FRC FPD fabrication is based on the use of continuous unidirectional (bundle) glass fibers in a polymethylmethacrylate dimethacrylate resin matrix as the substructure for the FPD.

With FRC FPDs, there are two approaches to using fibers: one is based on conventional tooth preparation and lab-made restorations, while the other is based on the use of fibers in restorations. mini-invasive (conservative) by direct or indirect production. FRC system allows to use different containers even in the same FPD (combined type).⁴

For example, if clinical conditions allow the correct design of the FRC framework, removing old fillings may create space for occlusal support of the FRC framework or repairs that maintain the surface perfectly. It can be manufactured. Currently, there are a limited number of clinical studies on fiber reinforced FPDs in the dental literature. However, based on these results, it is reasonable to expect FRC prostheses to have a long life, especially for prostheses manufactured using the direct method.^{4,7,8}

This paper describes the technique involved using minimally invasive approach along with lab support.



CASE DESCRIPTION

CASE 1:

A thirty two-year-old patient reported to the Department of Prosthodontics and Crown and Bridge, at Postgraduate Clinic, Bharati Vidyapeeth Dental College and Hospital, Pune, with a chief complaint of missing upper right lateral incisor teeth and compromised aesthetics [FIG 1].

CLINICAL EXAMINATION:

The patient has a normal horizontal and vertical overlap, and canine protected occlusion. After consulting with the patient, it became clear that the high cost of treatment made it impossible to insert an implant to replace the missing tooth. To protect the material of the remaining teeth, the production of conventional fixed partial dentures was avoided and rejected by the patient. The treatment with a removable partial denture was also rejected as patient demanded fixed restoration. Traditional repair options using implants or crown-retaining FPDs remained open in the future. Indirectly manufactured FRC-FPDs have been selected to provide superior aesthetics, maintain tooth structure and delay more invasive treatments.

TREATMENT PLAN:

Diagnostic impressions were taken and casts were poured. The casts were mounted in occlusion to check for the occlusal clearance and the available space for tooth preparation on the palatal surfaces of the central incisor and canine adjacent to the edentulous area. Once the evaluation was done, patient was called for further treatment which included site preparation for the FRC-FPD.

The teeth were prepared on the palatal surface with a high-speed air turbine arotor (150000 speed with water cooling). The preparation was 1.5mm deep and 3mm wide with a rectangular shape which extended half the palatal surface of the teeth from the line angle. Post preparation the area was dried with air way syringe and a single impression technique was used with Putty (3M™ Express™ XT Putty Soft VPS Impression Material) and Light Body (3M™ Express™ VPS Impression Material). The impression of the lower arch was taken in alginate (Zhermack).

The VPS impression was sent to laboratory (K Dent, Kharadi, Pune) for cast pouring and the alginate impression was poured immediately due to its shelf life limitations. Later the VPS impression was poured in the laboratory by trained technician and the cast was retrieved. Following the cast retrieval, the composite reinforced light cure strip (Angelus Interlig Single Patient Strip ,Impregnated Glass Fiber) was cut in a size of 15mm and placed on the prepared site on the replicated cast at both the ends on the palatal surfaces of the prepared teeth [FIG 2]. After placement of the strip it was cured with a light cure gun (Optilux-501) for 20sec. Then the wax pattern was fabricated on the cured band with extending wings on the palatal surfaces of the teeth on the cast. Post fabrication of wax pattern a Putty index was obtained only on the buccal surface of the waxed up tooth that is to be replaced. Then the composite (Prime Dent USA Composite Syringes) that matched the patient's shade of natural teeth was chosen. The composite was layer by layer cured and the tooth was fabricated with Putty index in place, on the cast. Once the composite tooth was fabricated the whole prosthesis was removed from the cast and polished and cervical composite layering was done in order to match the gingival shade. Post polishing and final finishing of the prosthesis it was cemented into patient's mouth. The prepared teeth were air dried using three way syringe and the area was isolated with cotton rolls. After that the prosthesis was tried in patient's mouth and checked for shade matching, occlusion and was approved by the patient. Once the prosthesis was approved by the patient it was ready for cementation. The prepared teeth were acid etch with (37% phosphoric acid gel),and then thoroughly rinsed and air dried. Adhesive resins were applied according to the manufacturer's instructions (Scotchbond multipurpose adhesive, 3M ESPE, USA) to tooth surface and cured using light cure for 15sec. Then the (3M RelyX U200 Clicker Self Adhesive Resin Cement) dual cure resin cement was dispensed as a mixing pad and thoroughly mixed, after which it was applied on the surface of the prosthesis which will be bonded to the palatal surface of the prepared tooth surfaces. Then the excess cement was removed and cured using light cure for 10 sec. The articulating paper was then used and the prosthesis was checked for occlusion.



CASE 2:

A female patient age 30 reported to the department of Prosthodontics and Crown and Bridge, Bharati Vidyapeeth Dental College and Hospital, Pune, Postgraduate clinic with a chief complaint of missing teeth in the lower anterior region with compromised aesthetics.

CLINICAL EXAMINATION:

Clinical examination revealed missing teeth with 31 and 41 (fig 7,8). Also 32,42 were periodontally compromised with Grade 1 mobility. The patient was given multiple treatment options after evaluation of the diagnostic casts, radiographs and systemic examination. The treatment options given to the patient was Implant supported bridge, Conventional Fixed Partial Denture, Removable Partial Denture. Patient wanted to avoid invasive procedure and hence the implant supported bridge was ruled out. Patient had periodontally compromised 32 and 42 abutment teeth and hence the conventional Fixed Partial Denture was also ruled out. Patient wanted a fixed prosthesis and hence removable denture was excluded.

TREATMENT PLAN:

The patient was thoroughly diagnosed and diagnostic impressions were taken and casts were poured. The casts were mounted in occlusion to check for the occlusal clearance. After discussion with the patient, it was concluded that a minimally invasive approach of Fiber Reinforced Composite Fixed Partial Denture was chosen as the optimum treatment option for the patient. Once the evaluation was done, patient was called for further treatment which included site preparation for the FRC-FPD.

The lingual surfaces of 32 and 42 were prepared with a rectangular box extending from the mesial axial surface 3mm to the center of the tooth and 1.5mm deep. Such preparation was done on lingual surface of 32 and 42 and the preparation finished and polished. Once the preparation was done, the area was isolated with cotton rolls and the teeth dried. Putty (3M™ Express™ XT Putty Soft VPS Impression Material) impression was made followed by light body (3M Express™ VPS Impression impression) (FIG 9). The impression was inspected for any voids and was poured in dental stone III. Then an impression was made of the upper arch using alginate (Zhermack), and poured. After the casts were retrieved, they were mounted in occlusion and sent to lab (K DENT Laboratory, Kharadi, PUNE) for fabrication of the prosthesis. The composite reinforced light cure strip (Angelus Interlig Single Patient Strip,

Impregnated Glass Fiber strip) was cut in a size of 25mm and placed on the prepared surfaces of the teeth on the cast, after which it was cured with a curing light (Optilux-501). Once the strip was hard, wax up was done and putty index was made of the waxed-up teeth only on the buccal surface. The index was then used to layer by layer built up the teeth with composite (Prime Dent USA Composite Syringes) over the strip and then cured. Gingival layered composite resin was used to cover the cervical portion of the prosthesis thus covering the associated soft tissue defect. After the prosthesis was fabricated, it was removed from the cast and polished. Once the prosthesis was completed, the patient was called for cementation of the prosthesis. The prosthesis was tried in patients' mouth and checked for aesthetics, phonetics and occlusion. Once it was confirmed by the patient, the area was air dried and isolated using cotton rolls. After which the prepared teeth were acid etch with 37% phosphoric acid for 20 sec and then rinsed off. Then bonding agent (Scotchbond multipurpose adhesive, 3M ESPE, USA) was applied over the prepared surfaces and cured using UV light. Post application of bonding agent, the prosthesis was cemented using Relyx U200 resin-based cement and cured for 15 sec. The prosthesis was again checked for retention, occlusion, aesthetics and phonetics (FIG 10). The patient was re-called at an interval of 1month, 3months and 6months.⁹

DISCUSSION:

The FRC-FPD is a technique that should be employed as and where possible as it a cost-effective and time saving alternative to the conventional removable partial denture in which the patient also gets a psychological advantage of a fixed prosthesis. The treatment also is conservative and requires minimal preparation of abutment and also minimum appointments. The prognosis of the prosthesis is also satisfactory and should be considered as a viable treatment option even in cases where the final treatment has to be delayed.

CLINICAL SIGNIFICANCE:

The treatment with FRC-FPD should be considered as a treatment option in clinical practice as it is a cost-effective and time saving treatment modality and also should be considered as a highly aesthetic fixed alternative to conventional Fixed Partial Denture or Maryland Bridge. It can suffice the function of both temporary and permanent treatment option according to the patient needs.

ACKNOWLEDGEMENT:



The authors are thankful to MR. ABHISHEK AND ABHIJEET KAMBLE (Certified Dental Technician, K DENT LABORATORY, KHARADI, PUNE, INDIA) for their lab support and technical expertise in the fabrication of the prosthesis.

REFERENCES

1. Aydin MY, Kargül B. Glass-fiber reinforced composite in management of avulsed central incisor: a case report. *Journal of Dentistry for Children*. 2004;71(1):66–68. [[PubMed](#)] [[Google Scholar](#)] [[Ref list](#)]
2. Akin H, Turgut M, Coskun ME. Restoration of an anterior edentulous space with a unique glass fiber-reinforced composite removable partial denture: a case report. *Journal of Esthetic and Restorative Dentistry*. 2007;19(4):193–197. [[PubMed](#)] [[Google Scholar](#)] [[Ref list](#)]
3. Butterworth C, Ellakwa AE, Shortall A. Fibre-reinforced composites in restorative dentistry. *Dental Update*. 2003;30(6):300–306. [[PubMed](#)] [[Google Scholar](#)]
4. Vallittu PK, Sevelius C. Resin-bonded, glass fiber-reinforced composite fixed partial dentures: a clinical study. *Journal of Prosthetic Dentistry*. 2000;84(4):413–418. [[PubMed](#)] [[Google Scholar](#)]
5. Vallittu PK. Flexural properties of acrylic resin polymers reinforced with unidirectional and woven glass fibers. *The Journal of Prosthetic Dentistry*. 1999;81(3):318–326. [[PubMed](#)] [[Google Scholar](#)]
6. Kim SH, Watts DC. Effect of glass-fiber reinforcement and water storage on fracture toughness (KIC) of polymer-based provisional crown and FPD materials. *International Journal of Prosthodontics*. 2004;17(3):318–322. [[PubMed](#)] [[Google Scholar](#)]
7. Vallittu PK. Survival rates of resin-bonded, glass fiber-reinforced composite fixed partial dentures with a mean follow-up of 42- months: a pilot study. *Journal of Prosthetic Dentistry*. 2004;91(3):241–247. [[PubMed](#)] [[Google Scholar](#)]
8. Monaco C, Ferrari M, Miceli GP, Scotti R. Clinical evaluation of fiber-reinforced composite inlay FPDs. *International Journal of Prosthodontics*. 2003;16(3):319–325. [[PubMed](#)] [[Google Scholar](#)]
9. Ahmed KE, Li KY, Murray CA. Longevity of fiber-reinforced composite fixed partial dentures (FRC FPD)-Systematic review. *J Dent*. 2017 Jun;61:1-11. doi: 10.1016/j.jdent.2016.08.007. Epub 2017 Mar 26. PMID: 28356189.

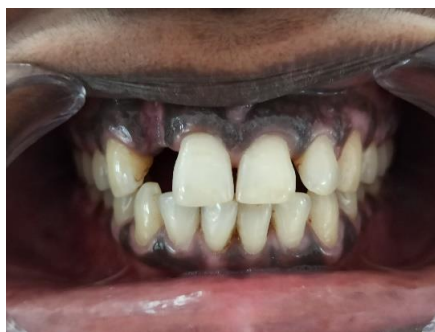

FIG 1

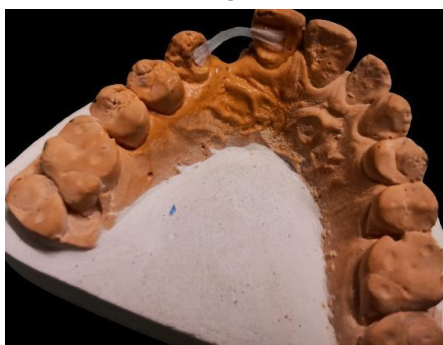

FIG 2

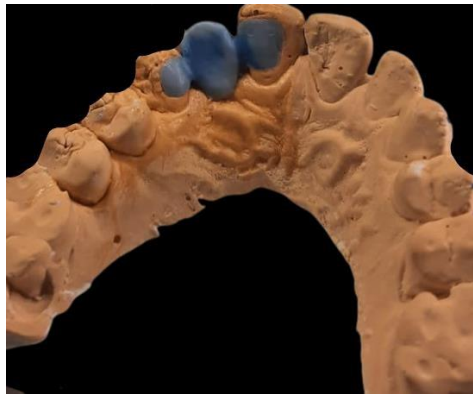


FIG 3

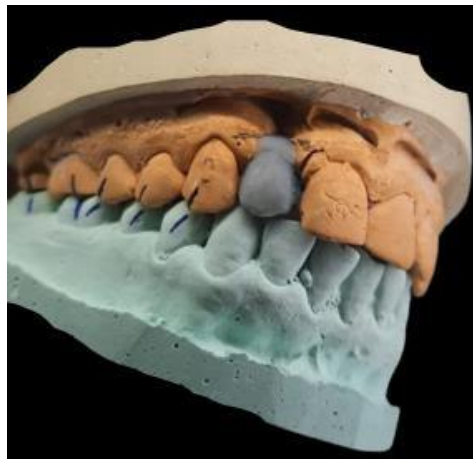

FIG 4

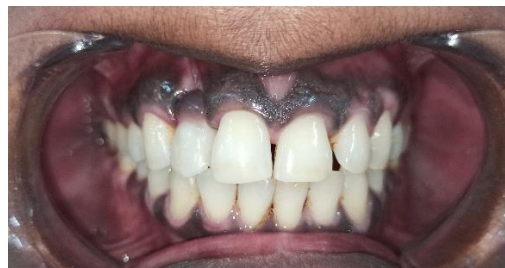

FIG 5

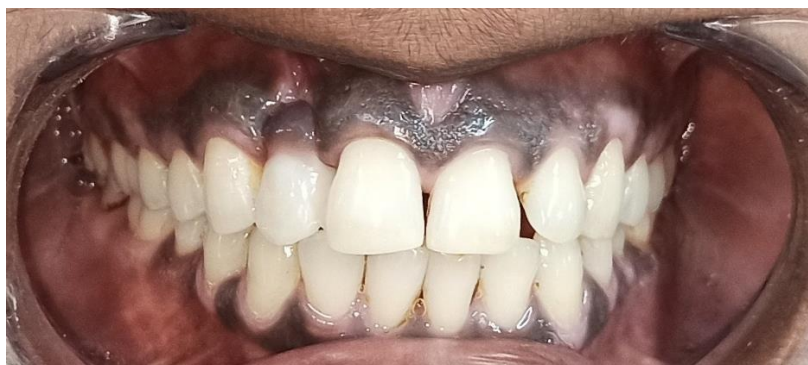

FIG 6

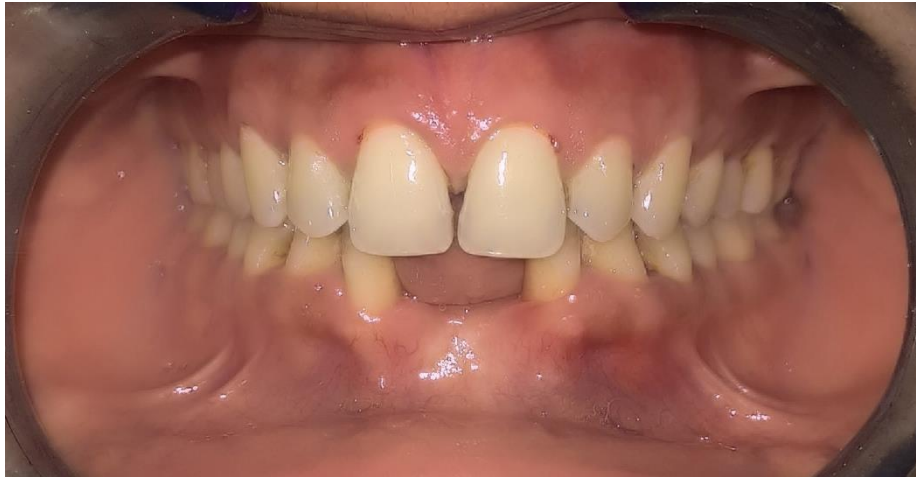

FIG 7

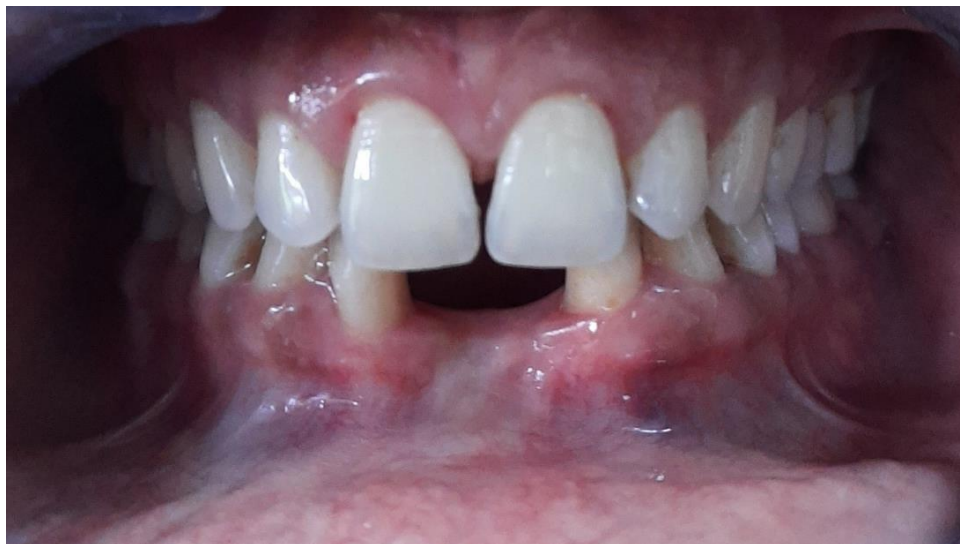

FIG 8

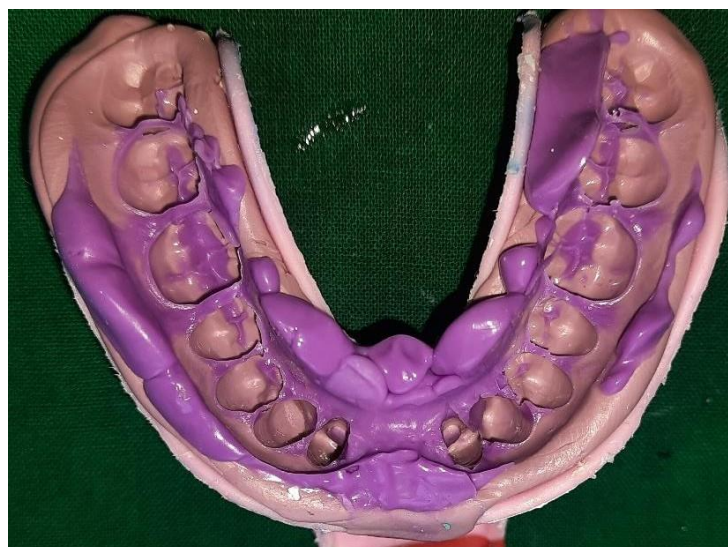

FIG 9

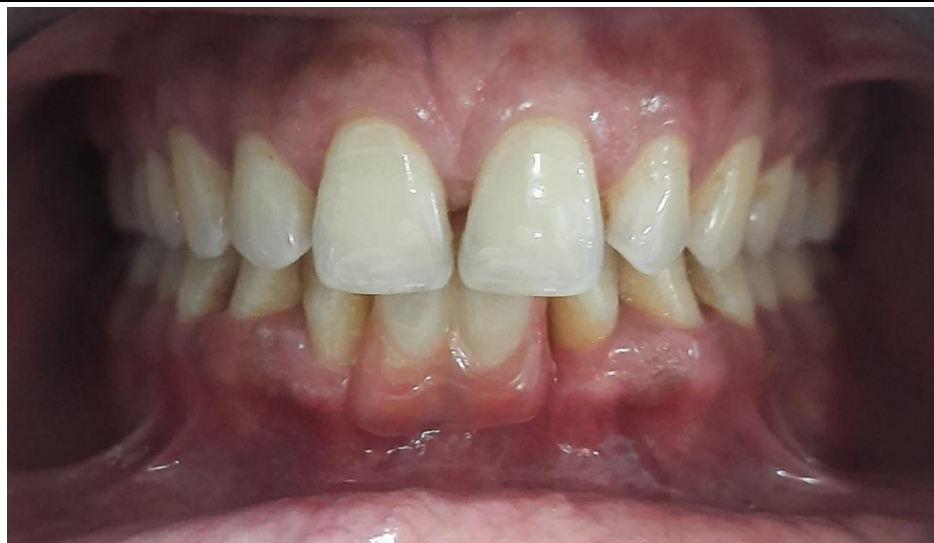

FIG 10