



## Treatment Strategies in Multivisceral Gist-A Case Series

Revanth<sup>1\*</sup>, Bhushan Hemraj Mahajan<sup>2</sup>, Saravanan P.S<sup>3</sup>, Amit Rai<sup>4</sup>, Suresh Babu<sup>5</sup>

<sup>1\*2</sup> Post Graduate Student, Department of General Surgery, Meenakshi Medical College, Hospital and Research Institute, Kanchipuram

<sup>3</sup>Head of Department, Department of General Surgery, Meenakshi Medical College, Hospital and Research Institute, Kanchipuram

<sup>4</sup>Assistant Professor, Department of General Surgery, Meenakshi Medical College, Hospital and Research Institute, Kanchipuram

<sup>5</sup>Associate Professor, Department of General Surgery, Meenakshi Medical College, Hospital and Research Institute, Kanchipuram

Received: 06 January 2023

Revised: 23 February 2023

Accepted: 11 March 2024

### KEYWORDS

GIST,  
Gastrointestinal  
Stromal Tumor,  
Perforation,  
Treatment  
Strategies

### Abstract

**Background:** There aren't many well-controlled research evaluating the perioperative results of OPD with MIPD. **Methodology:** This was a retrospective study of elective MIPD and OPD performed at 120 visiting Department of General Surgery, Meenakshi Medical College, Hospital and Research Institute, Kanchipuram. The NSQIP program collects more than 150 variables from 500 participating hospitals, including preoperative, intraoperative, and 30-day postoperative mortality, and morbidity outcomes. **Results:** 334 (7.4%) of the 4484 patients who were found underwent MIPD. Patients with MIPD were less likely to lose weight, younger, and more likely to be White. They were more likely to have a drain installed and to have a classic Whipple procedure. Following a 3:1 matching procedure, 334 MIPD patients and 1002 OPD patients were compared. Individuals with MIPD exhibited decreased rates of transfusion (7.9% vs. 14.4%;  $P = 0.02$ ) and total surgical site infection (13.4% vs. 19.6%;  $P = 0.04$ ), according to a secondary analysis comparing MIPD without conversion or open assist with OPD. **Conclusions:** Although an increased readmission rate somewhat offsets the advantages of a lower incidence of prolonged length of stay, MIPD had an identical morbidity and death rate to OPD.

### Introduction

The median diagnosis age for gastrointestinal stromal tumours (GISTs) is between 60 and 65 years old. GISTs typically occur in elderly adults. Younger patients are rarely diagnosed with GISTs. GISTs in children are stomach-based, frequently affect girls, and typically do not contain KIT/PDGFR mutations. It is unknown what the normal genotypic and phenotypic characteristics are for young people between the ages of 18 and 40. Less than 10% of GISTs are discovered in young individuals, or those under 40, and less than 1% are discovered in those under the age of 21.<sup>1</sup> Due in large part to the long-expected lifespan and active engagement in social and family life, as well as the effect of the disease on work, psychological issues, and fertility, this population's disease needs to be handled appropriately to maximise efficacy and tolerance. Young adulthood is a period of significant physical and psychosocial change, including continuing education, gaining financial independence, entering romantic relationships, starting a family, and raising children.<sup>2</sup> The illness and the way it is treated may make it challenging or impossible to go about

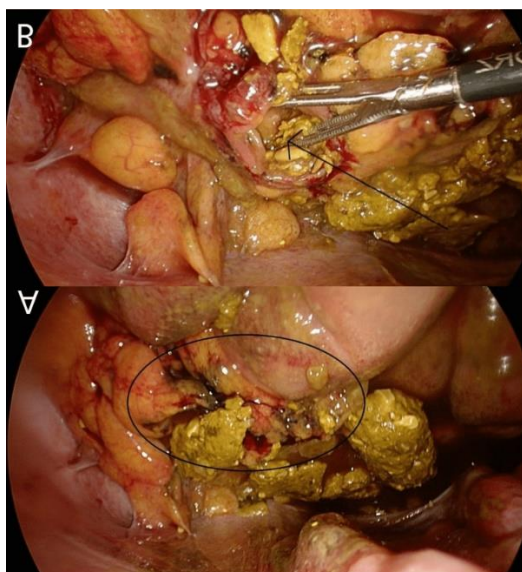
everyday activities. A team of professionals with experience treating soft tissue sarcomas should develop a management plan. This team should include specialists in nuclear medicine, pathology, radiology, gastroenterology, oncology, and medicine. The cornerstone of GIST treatments continues to be surgical therapy with R0 resection (negative margins), if feasible. Preoperative therapy may be started in certain situations. Adjuvant treatment is necessary for GISTs with high and intermediate risk.<sup>3</sup> Specialised medicines can be utilised for metastatic disease, however surgery may also be employed in certain circumstances. Owing to the molecular features of GISTs in young adults, special considerations on suitable therapy are required in order to present the best course of treatment for young GIST patients.

### Case

A male patient, age 74, who had a history of chronic obstructive pulmonary disease, arrived at the emergency room complaining of acute lower abdominal pain. Furthermore, the patient's pain persisted despite positive



findings from tests. A mid-to-lower intestine perforation, thought to be from the sigmoid or small bowel, was seen on an abdominal computed tomography (CT) scan. Also performed was a diagnostic laparoscopy. Figure 1 shows the results of the examination, which included diffuse peritonitis, faecal soiling of the entire abdomen, a 1.5 cm sigmoid colon perforation, and what looked to be a tiny tumour near the site.



**A laparoscopic view that reveals widespread peritonitis and widespread feces.**

A 1.5 cm sigmoid colon perforation. B) Little tumor (arrow) adjacent to the perforation

First things first, the entire abdomen was irrigated and faecal material was removed. Following a laparoscopic partial sigmoid resection, often known as the Hartmann surgery, the tumour was sent for pathological analysis. The tumour, which measures 0.7 cm and has a low mitotic rate, is found on gastrointestinal stromal tumour protein 1 (DOG-1) and is demonstrated to express cluster of differentiation (CD) 117, supporting the diagnosis of a GIST. No signs of perineural sheath involvement or lymphatic infiltration were present. Tumor-node-metastasis (TNM) classification of pT1 L0 V0 Pn0 R0 was given to the tumour. The tumour did not exhibit high-grade atypia or necrosis, and it had a spindle-like form under the microscope. It is also important to mention that the patient has had numerous post-operative problems, such as intermittent tachycardic atrial fibrillation, recurrent pleural effusion, urine retention, various abscesses, and sigmoid stump inadequacy. After receiving treatment for his difficulties over a few weeks, the individual was eventually released

from the hospital. It was found that the individual needed to have follow-up exams every six to twelve months. Nevertheless, the patient declined chemotherapy, so yearly CT scans are necessary.

### Methodology

We conducted an online search for GIST data and thoroughly examined every case report from September 16, 2023, to October 16, 2023. By conducting a search on National Centre for Biotechnology Information (NCBI)-PubMed and Embase with the terms "Gastrointestinal stromal tumour case report," all available studies were discovered. Patients with GIST, patients of both sexes, patients of different ages, patients with different body weights, and patients with different specific medically relevant habits were found to be included in the study. Patients with complications that could increase their risk of complications or influence the outcomes of the research were also excluded, as were those with terminal illnesses, multiple tumours, or tumours other than GIST. Additionally, patients who are likely to be lost to follow-up, miss data collection interviews, or provide false information were also excluded. All relevant English-language papers were examined, or those with pertinent English-language abstracts. The following were the search results: Out of the 341 publications (not duplicates), 274 were ignored since their research title or abstract did not include GIST in the main body of the work. Furthermore, after applying the inclusion and exclusion criteria, 47 publications were ignored throughout the data extraction procedure. The remaining 20 papers were all then added to this study, and they were all carefully evaluated and assessed.

### Results

Our review of the literature revealed that 21 patients—including the study case—were looked at in total; 14 (66.6%) of them were men and 7 (33.3%) were women. Their average age was 64.05. Their ages ranged from 30 to 85 years old. Sixty-nine percent of the patients were older than sixty. Most of the cases show that there were spindle cells with a high rate of mitosis within the tumour. Furthermore, as Table 1 illustrates, immunocytochemistry reveals that most patients have strong reactivity to particular antibodies like CD117, DOG-1, CD34, and vimentin being expressed.



Article	Age/years	Gender	Complaint	Site	Antibodies expressed
Present case	74 years	Male	Presented to the emergency department (ED) with severe abdominal pain	Sigmoid colon	CD117 (+) and DOG-1 (+)
Yuan et al., 2021 <sup>4</sup>	71 years	Male	Reported to the emergency room with a 38-hour history of intermittent hematochezia and diffuse abdominal pain	Small intestine (third jejunal segment)	CD117 (+), DOG-1 (+), SDHB (+), desmin (+), actin (+), CD34 (-), and S-100 (-)
Yang et al., 2022 <sup>5</sup>	59 years	Male	The patient's symptoms are consistent with incomplete obstruction: the patient felt unclean and noticed a shift in bowel habits with more frequent stools with a decrease in single stool volume	Rectum	CD117 (+), DOG-1 (+), CD34 (+), and Ki67 (+)
Tezcan and Koç, 2011 <sup>6</sup>	83 years	Male	Complaint of constipation and then one year later complaint of pain in the right hip	Rectum	CD117 (-), CD34 (-), S-100 (-), SMA (-), and desmin (-)
Sugimoto et al., 2013 <sup>7</sup>	52 years	Male	Complaint of anorexia and physical exhaustion	Upper stomach	CD117 (+), CD34 (+), S-100 (-), SMA (-), and desmin (-)
Manxhuka-Kerliu et al., 2014 <sup>8</sup>	30 years	Female	Presented with nausea, vomiting, and abdominal pain	Small intestine	CD117 (+), CD34 (+), vimentin (+), actin (+ focally), desmin (-), and S-100 (-)
Cheng et al., 2019 <sup>9</sup>	78 years	Female	Referred to the hospital with 10 days of ongoing vaginal bleeding and difficulty urinating	Cervical or rectal mass with rectovaginal invasion	CD117 (+), DOG-1 (+), H-caldesmon (+), actin and SMA (-), p40 (-), and S-100 (-)
Liu et al., 2018 <sup>10</sup>	72 years	Male	Complaint of upper abdominal pain for one month with regurgitation and weight loss	Gastric fundus	CD117 (+), vimentin (+), CD34 (+), S-100 (+), SMA (+), WT1 (-), Ki67 (-), and BCL-2 (-)
Wang et al., 2017 <sup>11</sup>	74 years	Female	Hospitalized as a result of worsening abdominal pain for two days with history or three months of abdominal pain and distention	Gastric fundus	CD117 (+), H-caldesmon (+), DOG-1 (+), SMA (weak +), CD34 (-), S-100 (-), desmin (-), and NSE (-)

## Discussion

Even though GIST is the most prevalent gastrointestinal mesenchymal tumour, there is still debate on its precise global prevalence because a comprehensive definition and classification are lacking. Still, 10–20 million individuals are thought to be affected by it.<sup>1</sup> The distribution of ages can vary significantly, with patients as young as 10 and as elderly as 100; the mid-60s was determined to be the average age. The separation of genders is equal. The colon (6.0%) and oesophagus (0.7%) are thought to be rare sites for GIST, while the stomach (55.6%) and small intestine (31.8%) are

thought to be the most common locations.<sup>12</sup> When it comes to colonic GIST in particular, the sigmoid colon is thought to be the most common region, followed by the transverse colon. Abdominal pain and bloating are two examples of ambiguous symptoms that help diagnose a GIST. More precisely, unclear symptoms are caused by gastric and small intestinal tumours; on rare occasions, upper gastrointestinal tract bleeding and pain may manifest. On the contrary hand, colorectal GIST may present with bleeding and obstruction. Constipation, obstruction, pelvic and rectal pain, or the presence of a tumour upon physical inspection of the



rectal cavity are further early warning indicators. Anaemia, weight loss, and urine symptoms such as decreased stream strength or hesitation are sneaky indicators of colorectal GIST. Additionally, 14 GIST may present with no symptoms at all and be discovered by accident during scans or physical examinations. A tiny percentage of GIST may also be cancerous. GIST is present anywhere across the spectrum of malignant projections. While the majority of tumours with modest mitotic rates—less than five mitoses per 50 high-power fields (HPF)—are benign, a small fraction do develop metastases.<sup>15</sup> To classify a tumour as low risk, it is sufficient to combine a tiny tumour (less than 5 cm) with a low mitotic rate. More than five mitoses per 50 HPF and big tumours larger than 5 cm are also seen as indicators of increased risk. More than 50 mitoses per 50 HPF indicates high-grade malignant GIST, which can frequently spread intra-abdominally or to the liver. It is imperative to underscore that no lesion, regardless of its size and mitotic rate, can be categorically deemed benign.

### Conclusion

Although GIST is the most common gastrointestinal mesenchymal tumour, its actual worldwide occurrence is still up for question due to a lack of a clear diagnosis and categorization. Based on extant literature, our review of case reports has revealed that the majority of GISTs are spindle-shaped and located in the stomach. Furthermore, the majority of these tumours had a high mitotic rate and were larger than 5 cm. There are often symptoms associated with GIST, although most of these are nonspecific and could confuse the diagnosis. This may cause abrupt, excruciating pain, shock, as well as other symptoms like fatigue, nausea, vomiting, and constipation. The most effective treatment for GIST is resection, which is usually followed by chemotherapy. Furthermore, patients usually require lifetime monitoring.

### References

- Miettinen M., Lasota J. Gastrointestinal Stromal Tumors. *Gastroenterol. Clin. N. Am.* 2013;42:399–415.
- Janardan S.K., Wechsler D.S. Caught in the In-Between: Challenges in Treating Adolescents and Young Adults With Cancer. *JCO Oncol. Pract.* 2021;17:299–301.
- NCCN Clinical Practice Guidelines in Oncology (NCCN Guidelines) Gastrointestinal Stromal Tumors (GISTs) Version 1. 2022.
- A concealed inguinal presentation of a gastrointestinal stromal tumor (GIST): a case report and literature review. Yuan Y, Ding L, Tan M, Han AJ, Zhang X.
- A rare rectal gastrointestinal stromal tumor with indolent biological behavior: a case study. Yang J, Liu Y, Sun XJ, Ai ZW, Liu S. *Exp Ther Med.* 2022;24:641.
- Gastrointestinal stromal tumor of the rectum with bone and liver metastasis: a case study. Tezcan Y, Koç M. *Med Oncol.* 2011;28:0–6.
- A case of gastrointestinal stromal tumor with pneumomediastinum. Sugimoto M, Hikichi T, Shioya Y, et al. *Fukushima J Med Sci.* 2013;59:97–101
- Small intestinal gastrointestinal stromal tumor in a young adult woman: a case report and review of the literature. Manxhuka-Kerliu S, Sahatciu-Meka V, Kerliu I, Juniku-Shkololli A, Kerliu L, Kastrati M, Kotorri V. *J Med Case Rep.* 2014;8:321.
- Gastrointestinal stromal tumor presenting as a rectovaginal septal mass: a case report and review of literature. Cheng M, Liu CH, Horng HC, Chen YJ, Lo PF, Lee WL, Wang PH. *Medicine (Baltimore)* 2019;98:0.
- Gastric carcinoma with a gastrointestinal stromal tumor - a case report and literature review. Liu S, Liu H, Dong Y, Wang F, Wang H, Chen J. *Med Sci (Paris)* 2018;34:15–19.
- Giant gastrointestinal stromal tumor with predominantly cystic changes: a case report and literature review. Wang L, Liu L, Liu Z, Tian Y, Lin Z. *World J Surg Oncol.* 2017;15:220.
- Global epidemiology of gastrointestinal stromal tumours (GIST): a systematic review of population-based cohort studies. Søreide K, Sandvik OM, Søreide JA, Giljaca V, Jureckova A, Bulusu VR. *Cancer Epidemiol.* 2016;40:39–46.
- Clinicopathological features and prognosis of colonic gastrointestinal stromal tumors: evaluation of a pooled case series. Feng F, Tian Y, Liu Z, et al. *Oncotarget.* 2016;7:40735–40745
- Colorectal gastrointestinal stromal tumors: a brief review. Reddy RM, Fleshman JW. *Clin Colon Rectal Surg.* 2006;19:69–77.
- Diagnosis of gastrointestinal stromal tumors: a consensus approach. Fletcher CD, Berman JJ, Corless C, et al. *Hum Pathol.* 2002;33:459–465.
- Gastrointestinal stromal tumor. Stamatakos M, Douzinas E, Stefanaki C, Safioleas P, Polyzoou E, Levidou G, Safioleas M. *World J Surg Oncol.* 2009;7:61