



## Comparative Evaluation of Four Different Cordless Retraction Systems With Respect to Gingival Displacement – An in Vivo Study

Dr. Dhananjay Dhiren Sheth<sup>1</sup>, Dr. Ajay V. Sabane<sup>2</sup>, Dr. Bhagyashree Kalsekar<sup>3</sup>, Dr. Rupali Patil<sup>4</sup>, Dr. Paresh Gandhi<sup>5</sup>, Dr. Neel Doshi<sup>6</sup>

1. Post Graduate, Department of Prosthodontics and Crown and Bridge, Bharati Vidyapeeth Dental College and Hospital, Pune, Maharashtra, India
2. Professor and Head of The Department, Department of Prosthodontics and Crown and Bridge, Bharati Vidyapeeth Dental College and Hospital, Pune, Maharashtra, India
3. Assistant Professor, Department of Periodontology, Bharati Vidyapeeth Dental College and Hospital, Pune, Maharashtra, India
4. Lecturer, Department of Prosthodontics and Crown and Bridge, Bharati Vidyapeeth Dental College and Hospital, Pune, Maharashtra, India
5. Lecturer, Department of Prosthodontics and Crown and Bridge, Bharati Vidyapeeth Dental College and Hospital, Pune, Maharashtra, India
6. Professor, Department of Prosthodontics and Crown and Bridge, Bharati Vidyapeeth Dental College and Hospital, Pune, Maharashtra, India
7. Postgraduate, Department of Endodontics, Bharati Vidyapeeth Dental College and Hospital, Pune, Maharashtra, India.

**Corresponding author : Dr. Ajay V. Sabane**

(Professor and Head of The Department, Department of Prosthodontics and Crown and Bridge, Bharati Vidyapeeth Dental College and Hospital, Pune, Maharashtra, India)

**Received: 06 September 2023**

**Revised: 23 October 2023**

**Accepted: 11 November 2023**

### KEYWORDS

### ABSTRACT

#### 1. AIM:

The aim of the study was to evaluate and compare the effect of four cordless displacement systems on the amount of gingival displacement lateral and apical directions namely Merocel strips, Traxodent, 3M ESPE retraction pastes and Easy Stat.

#### 2. METHODOLOGY:

Clinical efficacy of gingival retraction systems was studied as an expression of adequate lateral and apical gingival displacement by indirect assessment of the sulcus dilation with 3D intraoral digital scanning. The study was conducted at the department of Prosthodontics, and Crown and Bridge, B.V.U Dental college and hospital, Pune, on the unprepared maxillary right and left first premolars of ten selected subjects (5males and 5 females) who work in hospital, while the measurements were done at the OM dental laboratory, Ahemadnagar.

The preliminary scans of maxillary right and left 1st premolar was made using 3Shape Trios intraoral scanner. The scan was then imported as STL file to the Exocad software. The tooth was sectioned buccolingually. One line passing through the height of contour of the sectioned tooth and the other passing through the crest of the sectioned gingiva. The distance between the two lines gives the amount of sulcular depth in lateral direction. For evaluating the apical displacement two points were selected on scans that were not sectioned. One point at the cusp tip of the tooth and the other point selected at the deepest point of the gingival crevice. The distance between the two points gave the amount of apical displacement of gingiva.

Four groups were designed for the purpose of recording gingival displacement.

- Group 1 -Traxodent, Hemodent Paste Retraction System.
- Group 2 - Easy Stat, Ammdent.
- Group 3 - MEROCEL, Medtronic, Xomed.
- Group 4 - 3M ESPE Retraction Capsule.



### 3. RESULTS:

Least amount of displacement seen with Easy Stat. Merocel strips showed promising results.

#### CONCLUSION:

Merocel strips showed promising results and should be considered as an effective material of gingival retraction.

**CLINICAL SIGNIFICANCE:** The cordless systems provided enough gingival displacement for the bulk of impression material to flow within the sulcus, thus recording the prepared and unprepared tooth structure and also retrieval of impression without tearing.

---

## INTRODUCTION

Increasing esthetic demands and patient's awareness have led Fixed Prosthodontics to play a major role in patient rehabilitation. Fixed prosthesis and its relation to soft tissue has to be considered vital for the long-term success and increased prognosis of the prostheses. The esthetics and the prosthetic fit of the final prosthesis depends on various important factors and the quality, design, and location of finish line is recognized to be a significant influencing factor<sup>1</sup>. It is therefore necessary to record the prepared, and a portion of the unprepared tooth structure along with the gingival margin<sup>2,3</sup>. This information allows the technician to design prosthesis to achieve adequate marginal integrity and emergence profile and thereby allowing harmony between the gingiva and restoration. Gingival tissue has to be displaced temporarily during impression making and also is important during tooth preparation and cementation of prosthesis. Gingiva needs to be displaced laterally as well as vertically<sup>4</sup>. Being popularly used the chemico-mechanical cord technique requires packing the cord into the sulcus that may cause pain and bleeding.<sup>5</sup> Cordless displacement techniques have recently been introduced and have exhibited a good measure of success. These systems work by injection of a paste into the gingival sulcus of the prepared tooth to achieve a chemical-mechanical displacement. These products have similar methods of application. Cordless displacement techniques overpower conventional cord techniques, by saving time, causing less discomfort to the patient, increased efficiency with respect to gingival displacement, less associated crevicular fluid flow, less application-generated pressure, and better maintenance of gingival health. Most research and studies equivocally stress that adequate displacement with least trauma to the tissues is an essential pre-requisite before making final impression and for the long-term success of the restoration. Therefore, this clinical study was designed, to evaluate and compare the effect of four cordless displacement systems on the amount of gingival displacement lateral and apical directions namely

Merocel strips, Traxodent, 3M ESPE retraction pastes and Easy Stat.

Recently, it was suggested that a novel retraction substance (Merocel, Merocel Co., Mystic, Conn.) be used in dentistry to remove gingival tissue without causing tissue damage prior to taking an impression. The synthetic material used in Merocel retraction strips is precisely and chemically isolated from hydroxylate polyvinyl acetate, a biocompatible polymer that results in a netlike strip free of detritus and free pieces.

Merocel retraction material was selected because it is an absorbing, haemostatic material commonly used in otorhinolaryngic, gastric, thoracic, and otoneurosurgical procedures. This study compared the effective gingival displacement produced by Merocel strips and the conventional retraction cord used with double cord technique.

A simple, soft, quick, and absorbent paste called Traxodent offers efficient hemostasis and retraction. The soft paste exerts light pressure on the sulcus while soaking up extra blood and crevicular fluid. The 15% aluminium chloride has an astringent action without causing irritation or tissue discoloration around it. The slim syringe's flexible tip makes applying Traxodent simple. It is easily rinsed away within two minutes, leaving an open, dry, and retracted sulcus.

With the invent of expasyl, dentists now have a device that offers a solution to some of the drawbacks of earlier tools and methods. Aluminum chloride is present in the Expasyl gingival retraction substance, which amplifies the hemostatic effect and produces gingival displacement of up to 2 mm. Clay, a "putty-like material," aids in the mechanical action. The use of the expasyl paste is painless, and the patient experiences little adverse effects in addition to the excellent outcomes in retraction. Astringent gingival retraction paste is a recently developed retraction paste for quick and painless sulcus retraction without the need for laborious techniques. Paste-based astringent gingival retraction agents are available. Pastes are generally easy to apply and don't hurt or hurt the patient needlessly.



When greater hemostasis or retraction is required by a clinician, Traxodent can be used alone or in combination with a retraction cap. Simply use Traxodent in place of the second cord, which is frequently the trickier to put, for dentists who like the double-cord approach.

## METHODOLOGY

The protocol for the clinical study and technique of testing is elaborated as follows:

### A) Selection of subjects:

This study was conducted on the unprepared maxillary right and left first premolars of ten selected subjects who work in B.V.U Dental college and hospital, Pune (5males and 5 females).

Inclusion Criteria laid down for the subjects were as follows: -

- 1) Age group of 20 – 40 years.
- 2) Sound gingival and periodontal health, clinically and radiographically verified.
- 3) Teeth of normal size and contour (no developmental anomaly or regressive age changes).
- 4) Maxillary left and right 1<sup>st</sup> premolar, buccal gingival surface (Thick gingival biotype according to Siebert and Lindhe classification of gingival biotype).
- 5) No local tissue abusing habits.
- 6) Systemically healthy with no medical history that could affect their periodontal condition.
- 7) Good oral hygiene with pocket depths,  $\leq 3$ mm.
- 8) No evidence of attachment loss or bleeding on probing or plaque accumulation.

Periodontal screening was done by using Gingival Index given by Loe and Silness (1964). Sulcus depth was gauged by inserting William's periodontal probe parallel to the long axis of the tooth until slight resistance was felt. Further, the subjects with no significant difference between the sulcus depth (average 2-3mm) at the transitional line angles and mid buccal areas of the premolars were included in the study. All of these volunteers were fully informed about the nature of the study and suitable consent form was obtained. The preliminary scans of maxillary right and left 1st premolar was made using 3Shape Trios intraoral scanner.<sup>6</sup> The scan was then imported as STL file to the Exocad software. The tooth was sectioned buccolingually, [FIG 5]. Two lines were drawn to check for lateral gingival displacement. One line passing through

the height of contour of the sectioned tooth and the other passing through the crest of the sectioned gingiva. The distance between the two lines gave the amount of sulcular depth in lateral direction. For evaluating the apical displacement two points were selected on scans that were not sectioned. One point at the cusp tip of the tooth and the other point selected at the deepest point of the gingival crevice. The distance between the two points gave the amount of apical displacement of gingiva. [FIG 6]

All the retraction systems were tested on upper right (14) and left premolars (24) of all the 10 volunteers by simple random sampling. First two gingival retraction systems (as assigned according to the study by the operator) were tested on both the premolars. Then, after 14 days of first session, when the gingival health was restored back to normal, the remaining two gingival retraction systems were tested on the same premolars as assigned.

In GROUP I the maxillary premolar region was isolated with cotton rolls and air-dried using three-way syringe. Traxodent was applied on the buccal gingival sulcus starting from mesio-labial line angle to the disto-labial of the right first premolar (14) [FIG 3] according to manufacturer's instruction and was in place for 2minutes. After that it was easily rinsed away.

In case of GROUP II i.e., Easy Stat retraction paste system, the isolation of maxillary left first premolar (24) [FIG 3] region was carried out in similar manner. Then the cartridge cap of Easy Stat was removed and the angled syringe type tip was inserted into the labial surface of the gingival sulcus. The cartridge along with the tip was loaded in dispenser with the tip laterally on the dispenser. The piston of the dispenser was advanced towards the cartridge by pressing the dispenser trigger several times so that the paste begins to come out. While injecting the paste, the tip was bent at an angle and then slowly injected into the sulcus starting from mesio-labial line angle to the disto-labial line angle of the tooth. A sufficient quantity of paste was placed to completely fill the sulcus, which produced blanching of the marginal gingiva. Easy Stat was left in place for 2 minutes (as per manufacturer's recommendation) after which it was thoroughly washed out with a jet of water from 3-way syringe. Easy Stat was completely removed before making post displacement scans.



In GROUP III the right first premolar region (14), it was isolated with cotton rolls and air-dried using three-way syringe. A piece of Merocel strip was cut into thin section with 8-10mm length and thickness corresponding to the sulcus depth just enough to displace the gingival tissue. Then, the cut piece of Merocel strip was gently packed using cord packer into the labial gingival sulcus starting from mesio-labial line angle to the disto-labial line angle of the tooth. The Merocel strip was placed in the sulcus with firm but gentle pressure. [FIG 4] The tip of the instrument was inclined slightly toward the area where the Merocel strip had already been placed. The strip was in place for 2.5 minutes according to the manufacturer's instruction and then removed just before taking post-operative scans.

In GROUP IV i.e. the 3M ESPE retraction paste system, the left first premolar (24) region was isolated using cotton rolls and the area was air dried using three-way syringe. The 3M ESPE capsule was loaded in the dispensing gun and was placed in a position where the thin nozzle of the dispensing gun was at an angle to the gingival sulcus and the tip being thin was made to place within the sulcus.<sup>7</sup> [FIG 4] The material was then slowly dispensed into the sulcus according to the manufacturer's instructions starting from the mesio buccal line angle to the distobuccal line angle. The material was left in place for 3 minutes according to instructions and then easily rinsed off just prior to making of post displacement scans. Once the materials were rinsed off, post-displacement scans were obtained using 3Shape Trios intraoral scanner and the files were exported to the EXOCAD software. The values were obtained digitally using the technique mentioned above and they were tabulated. The data obtained was subjected to statistical analysis. The paired 'T' test was used to analyze the difference in the pre-displacement and post-displacement values. After statistically analysis, it was found that the difference in pre-displacement and post-displacement values of the gingival sulcular width, was statistically significant ( $p < 0.05$ ) (TABLE 1). Pre- and post-displacement of gingival sulcus in apical direction were recorded by using the 3Shape Trios intraoral scanner. The measurements were made from the deepest point on the buccal gingival crevice of the tooth to the cusp tip of the tooth [FIG 6]. The observations thus obtained was tabulated and subjected to statistical analysis. The amount of apical displacement in all the four groups was calculated by subtracting the pre-displacement values (TABLE 4). The data obtained was subjected to

statistical analysis. The paired 'T' test was used to analyze the difference in the pre-displacement and post-displacement values. After statistically analysis, it was found that the difference in pre-displacement and post-displacement values of the gingival sulcular width, was statistically significant ( $p < 0.05$ ) (TABLE 5).

## RESULTS

This study was conducted on ten selected subjects who work in B.V.U Dental college and hospital, Pune of which 4 were males and 5 were females. The mean age was 38 of the selected subjects. The amount of lateral displacement in all the four groups was calculated by subtracting the pre-displacement values from the post-displacement values (TABLE 1).

The pre and post- displacement values of the four groups were: Group 1(0.33,0.39);

Group 2(0.307,0.432); Group 3(0.306,0.577); Group 4(0.338,0.493).

Post-displacement sulcus width values were compared between all the four groups using ANOVA test (TABLE 3). It was found that all the four gingival retraction systems produced highly significant amount of gingival displacement with Group 3 producing maximum displacement followed by Group 4, Group 2 and least displacement shown by Group 1. Comparison between all the four groups produced significant or highly significant amount of gingival displacement except Group 2 and Group 4. Amount of gingival displacement between Group 1 and Group 3 differ significantly.

Post-displacement of sulcus in apical direction sulcus displayed values which were compared between all the four groups using ANOVA test (TABLE 6). It was found that all the four gingival retraction systems produced highly significant amount of gingival displacement with Group 3 producing maximum displacement followed by Group 4, Group 2 and least displacement shown by Group 1.

Comparison between all the four groups produced significant or highly significant amount of gingival displacement in apical direction except Group 2 and Group 4. Amount of apical gingival displacement between Group 1 and Group 3 differ significantly. Significant differences were found among the 4 tested materials in both vertical and horizontal gingival displacement. Merocel strips, 3M ESPE, and Traxodent showed significant displacement with least amount of displacement seen with Easy Stat. Merocel strips showed promising results and should be considered as an effective material of gingival retraction when



compared to traditional cord retraction displacements systems.<sup>1</sup>

## Discussion

To effectively expose the sulcular area, the displacement force must be large enough to overcome the resistance produced by the gingival tissues while also preventing tissue collapse. Gingival resistance varies depending on the structure, health, and biotype of the tissue. In the interproximal gingiva, collagen fibres are thicker and more abundant. Thick interproximal bone supports thick dentogingival fibers, which might resist displacing forces. Unhealthy, inflamed, or swollen tissues are prone to collapse during impression making.

The results showed that the Merocel strips showed mean difference of 0.13mm in lateral displacement and 0.10mm in apical displacement which was maximum when compared amongst all the groups. The p value was ( $p < 0.01$ ) which is statistically significant. This is because of the property of the material to absorb the gingival crevicular fluid and swell, causing a mechanical displacement of the gingival sulcus. The pressure used to place the strip in the sulcus was minimum thus causing minimal trauma to the gingival tissues and minimum bleeding. Amongst all the groups the Group 2 (Easy Stat, Ammdent) showed the least displacement. This may be attributed to the chemical nature of Ferric sulphate and also the syringe system of application. As such there is no known research or study found in the literature concerning Easy Stat, and hence was one of the materials included in this study, to test its clinical efficacy. The difference in Group 1 and Group 4 was not much but Group 4 displayed more displacement as compared to Group 1 (Traxodent, Hemodent) due to the thin nozzle and the design of the retraction system of (3M ESPE) which caused a deeper insertion of the tip of nozzle into the gingival sulcus which allowed a better delivery of the material into the sulcus and with pressure within the physiologic limits to displace the gingival sulcus in a chemico-mechanical method.

According to the study conducted by Acar Ö et al, the Traxodent retraction paste system showed almost equal amount of gingival displacement when compared with impregnated cords.<sup>6</sup> These results are in accordance with the present study.

Rayyan MM et al compared four cordless retraction materials and the conclusions were that amongst the four materials compared in the study, two of which were Traxodent and 3M ESPE, the Traxodent could minimally displace the gingiva when compared to 3M

ESPE which could achieve the minimum displacement criteria of 200micrometre.<sup>7</sup>

Qureshi, S. M. et al, too concluded in their study that astringent gingival retraction paste (3M ESPE) showed the highest value for gingival displacement.<sup>8</sup>

The difference among the displacement of the gingival sulcus between various systems is attributed to their design of the dispensing system and the chemical nature of the material.

Ferrari M et al, conducted a study to evaluate the Merocel strip as a new material in gingival retraction and the results proved that Merocel retraction material is capable of innocuously expanding the gingival sulcus and also a predictable retraction material in conjunction with impression procedures.<sup>9</sup> The results are in accordance with this study.

Shivasakthy M et al, studied various gingival retraction materials and described in their study that Merocel retraction material is chemically pure, easy to shape, extremely effective for intraoral fluid absorption such as saliva, blood, and crevicular fluid, is soft and adaptation to surrounding tissues is also easy, and is devoid of pieces or debris, and alsonon-abrasive.<sup>10,11,12</sup> The results are in accordance with one observed in this study.

The current study has limitations, such as evaluating materials solely around healthy teeth. More research is needed with a larger sample size to analyze the same factors in diverse populations and over longer periods of time. The material's effectiveness in the presence of gingivitis and periodontitis, as well as different gingival thickness groups, should be investigated. The materials can be tested on prepared teeth with different finish lines, for the study to have a wider reach.

## CONCLUSION

Within the limitations of this clinical study, it was concluded that, Significant differences were found among the 4 tested materials in both vertical and horizontal gingival displacement.<sup>13,14</sup> Merocel strips showed promising results and should be considered as an effective material of gingival retraction when compared to traditional cord retraction displacements systems.<sup>2,15,16</sup> The cordless paste systems, satisfied the minimum requirement of gingival displacement and also has advantages of ease of use, sufficient gingival displacement and minimal haemorrhage and soft tissue damage, and can be considered as an effective alternative to retraction cord systems.<sup>1,17,18</sup>





## REFERENCES

1. Dederichs M, Fahmy MD, Kuepper H, Guentsch A. Comparison of Gingival Retraction Materials Using a New Gingival Sulcus Model. *J Prosthodont.* 2019 Aug;28(7):784-789. doi: 10.1111/jopr.13093. Epub 2019 Jun 27. PMID: 31206914.
2. Weir DJ, Williams BH. Clinical effectiveness of mechanical-chemical tissue displacement methods. *J Prosthet Dent.* 1984 Mar;51(3):326-9. doi: 10.1016/0022-3913(84)90214-2. PMID: 6368802.
3. Rajambigai, M Aarti et al. "Quick, painless, and atraumatic gingival retraction: An overview of advanced materials." *Journal of pharmacy & bioallied sciences* vol. 8, Suppl 1 (2016): S5-S7. doi:10.4103/0975-7406.191968.
4. Bowles WH, Tardy SJ, Vahadi A. Evaluation of new gingival retraction agents. *J Dent Res.* 1991 Nov;70(11):1447-9. doi: 10.1177/00220345910700111101. PMID: 1960257.
5. Bennani V, Inger M, Aarts JM. Comparison of pressure generated by cordless gingival displacement materials. *J Prosthet Dent.* 2014 Aug;112(2):163-7. doi: 10.1016/j.prosdent.2013.09.035. Epub 2014 Feb 14. PMID: 24529659..
6. Acar Ö, Erkut S, Özçelik TB, Ozdemir E, Akçil M. A clinical comparison of cordless and conventional displacement systems regarding clinical performance and impression quality. *J Prosthet Dent.* 2014 May;111(5):388-94. doi: 10.1016/j.prosdent.2013.08.009. Epub 2013 Dec 18. PMID: 24360008.
7. Rayyan MM, Hussien ANM, Sayed NM, Abdallah R, Osman E, El Saad NA, Ramadan S. Comparison of four cordless gingival displacement systems: A clinical study. *J Prosthet Dent.* 2019 Feb;121(2):265-270. doi: 10.1016/j.prosdent.2018.05.010. Epub 2018 Oct 26. PMID: 30722986.
8. Qureshi SM, Anasane NS, Kakade D. Comparative Evaluation of the Amount of Gingival Displacement Using Three Recent Gingival Retraction Systems - *In vivo* Study. *Contemp Clin Dent.* 2020 Jan-Mar;11(1):28-33. doi: 10.4103/ccd.ccd\_311\_19. Epub 2020 Jul 13. PMID: 33110305; PMCID: PMC7580752.
9. Ferrari M, Cagidiaco MC, Ercoli C. Tissue management with a new gingival retraction material: a preliminary clinical report. *J Prosthet Dent.* 1996 Mar;75(3):242-7. doi: 10.1016/s0022-3913(96)90479-5. PMID: 8648569.
10. Shivasakthy M, Asharaf Ali S. Comparative Study on the Efficacy of Gingival Retraction using Polyvinyl Acetate Strips and Conventional Retraction Cord - An in Vivo Study. *J Clin Diagn Res.* 2013 Oct;7(10):2368-71. doi: 10.7860/JCDR/2013/6980.3526. Epub 2013 Sep 16. PMID: 24298531; PMCID: PMC3843446.
11. Benson BW, Bomberg TJ, Hatch RA, Hoffman W Jr. Tissue displacement methods in fixed prosthodontics. *J Prosthet Dent.* 1986 Feb;55(2):175-81. doi: 10.1016/0022-3913(86)90336-7. PMID: 3514852.
12. Hong LG, Guo LP, Xue LL. [Gingival retraction paste versus gingival retraction cord for fixed prosthodontics: a systematic review]. *Shanghai Kou Qiang Yi Xue.* 2013 Aug;22(4):456-61. Chinese. PMID: 24100909.
13. Rayyan MM, Hussien ANM, Sayed NM, Abdallah R, Osman E, El Saad NA, Ramadan S. Comparison of four cordless gingival displacement systems: A clinical study. *J Prosthet Dent.* 2019 Feb;121(2):265-270. doi: 10.1016/j.prosdent.2018.05.010. Epub 2018 Oct 26. PMID: 30722986.
14. Shivasakthy M, Asharaf Ali S. Comparative Study on the Efficacy of Gingival Retraction using Polyvinyl Acetate Strips and Conventional Retraction Cord - An in Vivo Study. *J Clin Diagn Res.* 2013 Oct;7(10):2368-71. doi: 10.7860/JCDR/2013/6980.3526. Epub 2013 Sep 16. PMID: 24298531; PMCID: PMC3843446.
15. Huang C, Somar M, Li K, Mohadeb JVN. Efficiency of Cordless Versus Cord Techniques of Gingival Retraction: A Systematic Review. *J Prosthodont.* 2017 Apr;26(3):177-185. doi: 10.1111/jopr.12352. Epub 2015 Sep 17. PMID: 26378615.
16. Mehta S, Virani H, Memon S, Nirmal N. A Comparative Evaluation of Efficacy of Gingival Retraction Using Polyvinyl Siloxane Foam Retraction System, Vinyl Polysiloxane Paste Retraction System, and Copper Wire Reinforced Retraction Cord in Endodontically Treated Teeth:



An *in vivo* Study. Contemp Clin Dent. 2019 Jul-Sep;10(3):428-432. doi: 10.4103/ccd.ccd\_708\_18. PMID: 32308315; PMCID: PMC7150559.

17. Gupta A, Prithviraj DR, Gupta D, Shruti DP. Clinical evaluation of three new gingival retraction systems: a research report. J Indian Prosthodont Soc. 2013 Mar;13(1):36-42. doi: 10.1007/s13191-012-0140-y. Epub 2012 Jul 8. PMID: 24431705; PMCID: PMC3602524.

18. Kesari ZI, Karani JT, Mistry SS, Pai AR. A comparative evaluation of amount of gingival displacement produced by four different gingival displacement agents - An *in vivo* study. J Indian Prosthodont Soc. 2019 Oct-Dec;19(4):313-323. doi: 10.4103/jips.jips\_288\_19.

FIGURES

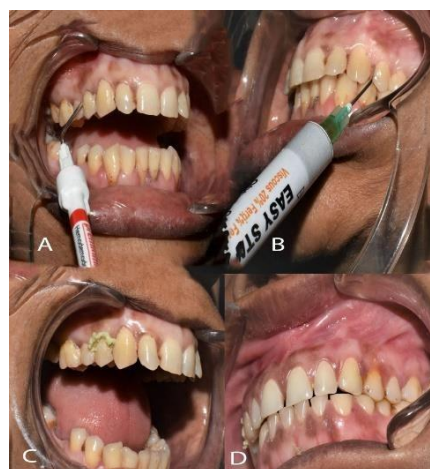

Figure 1: A) Application of Traxodent; B) Traxodent Retraction System in place; C) Application of Easy Stat; D) Easy Stat in place.

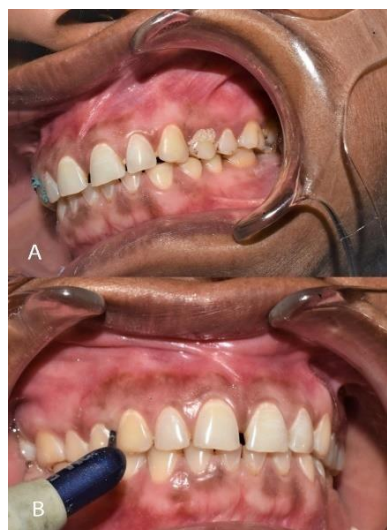

Figure 2: A) Merocel strip in place; B) shows application of 3M ESPE retraction system.




Figure 3: A) Shows pre-displacement scan and sectioned tooth in bucco-lingual direction; B) post displacement scan and sectioned tooth in bucco-lingual direction.

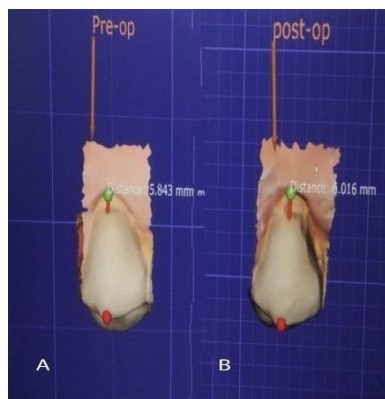


Figure 4: A) Shows pre-displacement scan and apical gingival displacement; B) Post displacement scan and apical gingival displacement.

TABLES

**Table No. 1:** - Data of the Pre- and Post-laterally displaced gingival sulcus in all the four groups. (All values in millimetres)

Serial No. I	<b>Group I</b> Traxodent, Hemodent Paste (System). 15% Aluminium Chloride		<b>Group II</b> Easy Stat, Ammdent 20% Viscous Ferric Sulphate		<b>Group III</b> MEROCEL, Medtronic, Xomed) Poly-vinyl acetate strips		<b>Group IV</b> 3M ESPE Retraction Capsule 15% Aluminum chloride hexahydrate	
	Pre-displacement Ia	Post-displacement Ib	Pre-displacement IIa	Post-displacement IIb	Pre-displacement IIIa	Post-displacement IIIb	Pre-displacement IVa	Post-displacement IVb
1	0.32	0.38	0.27	0.35	0.3	0.43	0.32	0.42
2	0.3	0.37	0.29	0.37	0.33	0.48	0.34	0.42
3	0.4	0.47	0.3	0.38	0.29	0.4	0.3	0.43
4	0.3	0.37	0.31	0.4	0.3	0.43	0.35	0.45





5	0.29	0.37	0.28	0.35	0.35	0.47	0.33	0.40
6	0.27	0.33	0.35	0.42	0.27	0.4	0.40	0.5
7	0.35	0.4	0.3	0.39	0.3	0.42	0.38	0.49
8	0.3	0.37	0.33	0.4	0.32	0.5	0.32	0.40
9	0.4	0.46	0.35	0.41	0.28	0.4	0.3	0.38
10	0.37	0.42	0.29	0.35	0.32	0.44	0.34	0.42
Mean	0.33	0.390	0.307	0.432	0.306	0.577	0.338	0.493

**Table 2:** Intergroup comparison of post displacement (Test applied Multiple measures ANOVA)

Post	N	Mean±SD	p-Value
Group1	10	0.39±0.04	0.01*
Group2	10	0.43±0.02	
Group3	10	0.57±0.03	
Group4	10	0.49±0.03	

**Table 3:** Intergroup comparison of mean difference between post displacement (Bonferroni post hoc test)

		Mean Difference	p-Value
Group 1	Group2	0.01	1
	Group 3	-0.04	0.77
	Group 4	-0.03	0.18
Group 2	Group 1	-0.01	1
	Group 3	-0.05	0.01*
	Group 4	-0.04	0.03*
Group 3	Group 1	0.04	0.07
	Group 2	0.05	0.11
	Group 4	0.006	1
Group 4	Group 1	0.03	0.18
	Group 2	0.04	0.30
	Group 3	-0.006	1

**Table No. 4:** - Data of the Pre- and Post-apically displaced gingival sulcus in all the four groups. (All values in millimetres)

Serial No. I	<b>Group I</b> Traxodent, Hemodent Paste Retraction System). Aluminium Chloride		<b>Group II</b> Easy Stat, Ammdent 20% Viscous Ferric Sulphate		<b>Group III</b> MEROCEL, Medtronic, Xomed) Poly-vinyl acetate strips		<b>Group IV</b> 3M ESPE Retraction Capsule 15% Aluminum chloride hexahydrate	
	Pre-displacement Ia	Post-displacement Ib	Pre-displacement IIa	Post-displacement IIb	Pre-displacement IIIa	Post-displacement IIIb	Pre-displacement IVa	Post-displacement IVb
1	0.5	0.53	0.45	0.49	0.6	0.7	0.55	0.63
2	0.56	0.59	0.5	0.53	0.58	0.68	0.6	0.65



3	0.59	0.61	0.55	0.59	0.55	0.67	0.65	0.7
4	0.6	0.62	0.53	0.57	0.6	0.7	0.6	0.65
5	0.64	0.66	0.58	0.63	0.54	0.63	0.58	0.64
6	0.55	0.59	0.6	0.62	0.59	0.67	0.6	0.66
7	0.62	0.63	0.58	0.60	0.6	0.69	0.54	0.60
8	0.6	0.61	0.6	0.65	0.6	0.68	0.62	0.7
9	0.58	0.59	0.49	0.52	0.55	0.67	0.6	0.67
10	0.6	0.62	0.54	0.59	0.55	0.65	0.59	0.66
Mean	0.584	0.605	0.542	0.579	0.576	0.674	0.593	0.65

**Table 5:** Intergroup comparison of post displacement (Multiple measures ANOVA)

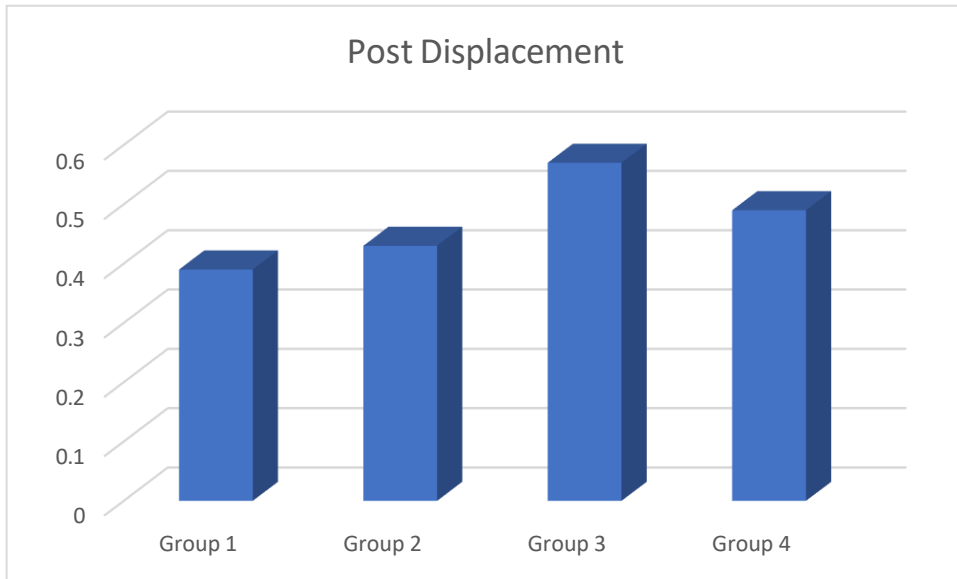
Post	N	Mean±SD	p-Value
Group1	10	0.60±0.03	0.01*
Group2	10	0.57±0.05	
Group3	10	0.67±0.02	
Group4	10	0.65±0.03	

**Table 6:** Intergroup comparison of mean difference between post displacement (Bonferroni post hoc test)

		Mean Difference	p-Value
Group 1	Group2	0.02	0.69
	Group 3	-0.06	0.01
	Group 4	-0.05	0.01
Group 2	Group 1	-0.02	0.69
	Group 3	-0.09	0.01
	Group 4	-0.07	0.01
Group 3	Group 1	0.06	0.01
	Group 2	0.09	0.01
	Group 4	0.01	1
Group 4	Group 1	0.05	0.01
	Group 2	0.07	0.01
	Group 3	-0.01	1

## GRAPHS

Graph 1: Intergroup comparison of post gingival displacement in lateral direction



Graph 2: Intergroup comparison of post gingival displacement in apical direction

