



## Accelerating Tooth Movement Using Cortically Induced Orthodontics - A Case Report.

Harshal Patil<sup>1</sup>, Nishita Kulkarni<sup>2</sup>, Tanaya Kulkarni<sup>3</sup>, Swapneel Bodele<sup>4</sup>, Vinit Swami<sup>5</sup>, Sukumar Lipare<sup>6</sup>

Assistant Professor, Department of Orthodontics and Dentofacial Orthopedics, Bharati Dental College and Hospital, Pune.

Associate Professor, Department of Conservative Dentistry and Endodontics, D.Y. Patil Dental School, Charholi Budruk, Pune.

Private practitioner and consulting Pedodontist, Sangli.

Private practitioner and consulting Periodontist, Nagpur.

Professor, Department of Orthodontics and Dentofacial Orthopedics, Bharati Dental College and Hospital, Pune.

Assistant Professor, Department of Orthodontics and Dentofacial Orthopedics, Bharati Dental College and Hospital, Pune.

Corresponding author- Dr. Tanaya Kulkarni

*(Received: 07 January 2024*

*Revised: 12 February 2024*

*Accepted: 06 March 2024)*

### KEYWORDS

Corticotomy,  
Periodontally  
accelerated  
osteogenic  
orthodontics  
(PAOO),  
Rapid acceleratory  
phenomenon (RAP).

### ABSTRACT:

In recent times, patients wish for quicker orthodontic treatments due to rising societal expectations, have high standards for the final result. In the present case, PAOO assisted fixed orthodontic employed to treat a patient who wished to get the treatment done faster. A twenty year old male pr Class I malocclusion with bimaxillary dento-alveolar protrusion with average to vertical growth spacing in upper and lower anteriors, convex profile and everted lower lip. Patient had tongue thr Fixed orthodontic mechano-therapy was performed with MBT prescription 0.022 slot and palata anchorage was devised for maxillary and mandibular arches. PAOO was utilized to reduce the tre: Proclination and spacing along with rotations of all teeth corrected. Vertical position of molars was Improvement in facial profile and lip incompetency was reduced.

### 1. Introduction

Adults seeking orthodontic treatment frequently demand shorter treatment duration. Adults have certain biological characteristics, that makes it challenging to reduce the treatment duration using conventional methods. With surgical initiatives providing the best success rates, many approaches have been continuously investigated and employed throughout the years to hasten tooth movement.<sup>1</sup>

Such surgical attempts have been proposed since 1959, when Kole postulated that cortical bone plates served as the primary obstacle to tooth movement.<sup>2</sup> As a result, a corticotomy/osteotomy technique that

selectively divided the plates was reported with encouraging outcomes.<sup>3</sup> Later the Wilcko brothers, developed a new method for surgically assisting tooth movement in orthodontics 2001. It was termed as Wilckodontics™ in scientific literature.<sup>4</sup>

Their method combined conventional corticotomies and osteotomies of the alveolar bone with the use of bone grafts. Due to its advantages over conventional orthodontics, Wilcko's novel "Periodontally Accelerated Osteogenic Orthodontic" (PAOO) technique has gained acceptance and popularity.<sup>5</sup>

Moderate to severe crowding, segmental or generalized spacing, Class II malocclusions needing

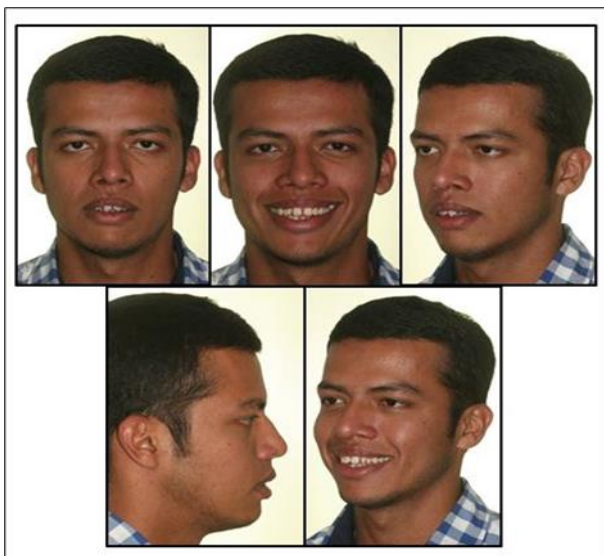

expansion and/or extractions, mild Class III malocclusions, extrusion for open bites, and intrusion for deep bites are the main indications for PAOO today.<sup>5</sup> Recently, it has also been proposed that PAOO could reduce the need for and extent of orthognathic surgery in particular patients, offering up newer prospects for maxillofacial surgery.<sup>6</sup>

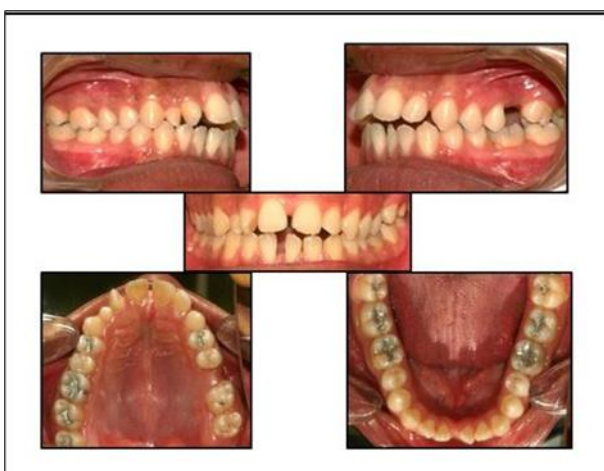**2. Case selection**

A patient aged twenty years, male, reported to the operatory with the chief complaint of spacing in upper and lower front teeth and wished to get it treated.

Clinical Features were as follows: (Fig. 1.a)



**Fig. 1 Pre-operative images, a. Extra-oral images.**



**Fig. 1 Pre-operative images, b. Intra-oral images**

Shape of head was dolicocephalic with leptoprosopic facial form & posterior divergence, convex profile. Class I skeletal relation was seen.

Clinical FMA was average with negative VTO & obtuse nasolabial angle.

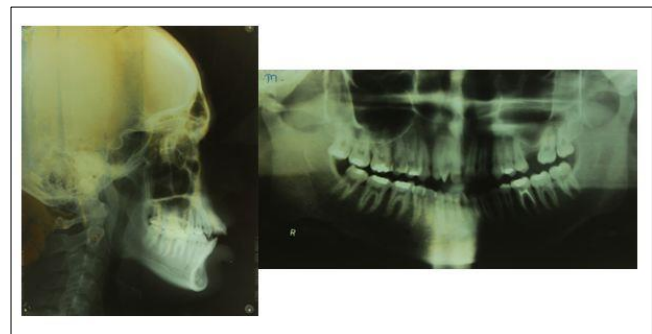Upper midline- midline shift to left side was present with Class I molar relation on right side, open bite with simple tongue thrust. (Fig. 1.b)

Post-pubertal age with average to vertical growth pattern.

**3. Problem List**

**Dental-** Class I molar occlusion with anterior open bite and spacing in upper and lower anterior teeth. (Fig 1.b)

**Skeletal-** Class II skeletal base with prognathic maxilla and orthognathic mandible. (Fig 2)



**Fig.2- Pre- orthodontic treatment radiographs**

**Dento-alveolar-** Bimaxillary dentoalveolar protrusion, spacing in upper and lower anteriors with dental open bite.

**Soft Tissue-** Convex profile with incompetent lips, everted lower lip.

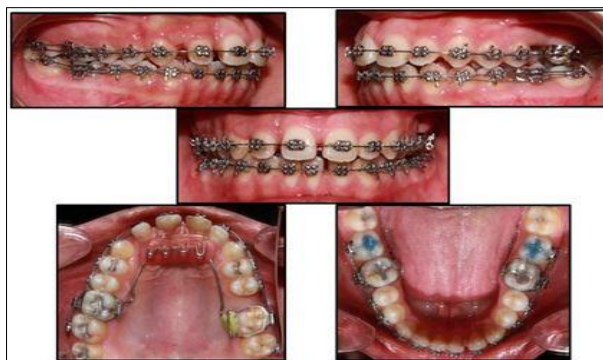**4. Diagnosis**

20 year old male presented with Class I malocclusion, bimaxillary dentoalveolar protrusion and class II skeletal bases, having average to vertical growth pattern with spacing in upper and lower anteriors, convex profile and everted lower lip.

**5. Treatment plan**

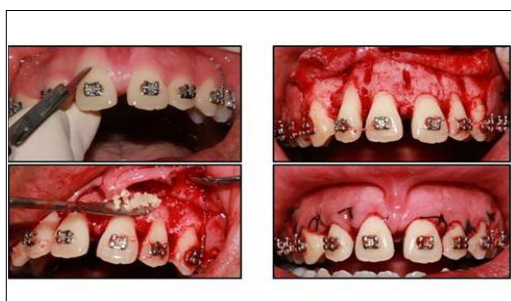


Extraction of the deciduous upper right lateral incisor was followed by fixed orthodontic mechano-therapy with MBT prescription 0.022 slot and palatal crib (Fig. 3.a). Protraction of Permanent maxillary left



second molar was done using mini implant.

**Fig. 3. Intra-operative images. a. Orthodontic phase,**



**Fig. 3. Intra-operative images, b. Surgical phase**

The surgical procedure for PAOO was performed according to the following steps- (Fig. 3b)

Flap reflection, decortication, particle grafting, closure, and application of orthodontic force. For the surgical procedure, after administering local anesthesia, a full-thickness mucoperiosteal flap was elevated extending 3–4 mm beyond the mucogingival junction. With the help of a round bur, under cold saline irrigation, vertical grooves were placed in the inter-radicular space. The vertical cuts extended 2–3 mm from the alveolar crest to approximately 2 mm beyond the apices of the roots. After the placement of the corticotomy cuts, required amount of Demineralized Freeze- dried Bone Allograft (DFDBA) was placed in the vertical corticotomy sites. The flap was adapted to normal position without tension and suturing was done

by non-resorbable silk suture. The sutures were left in place for eight days.

Anchorage Plan: Maxillary and Mandibular – maximum anchorage.

Retention Plan: Maxillary and Mandibular – Permanent bonded retainers.

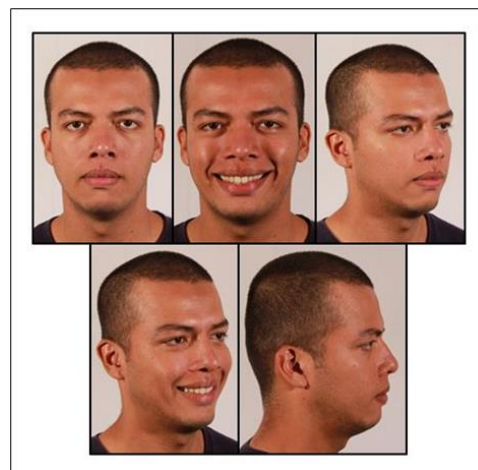## 6. Results

Facial Esthetics: Improvement in facial profile. Lip incompetency was reduced. (Fig. 4.a)

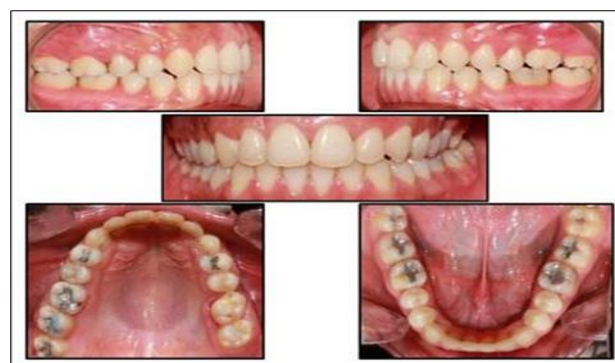Antero-posterior: Proclination and spacing along with rotations of all teeth corrected. (Fig. 4.b)

Retraction & uprighting of incisors in more favorable position and closure of all spaces was achieved. (Fig 5)

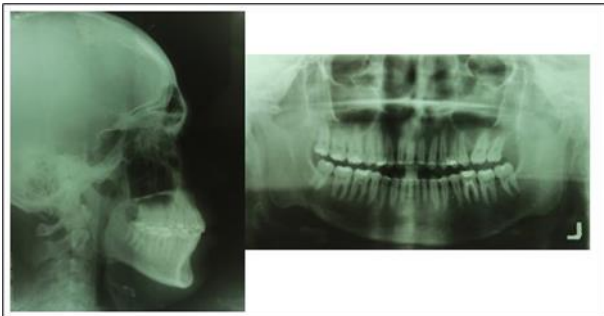
Class I molar relation was obtained, bilaterally.



**Fig. 4 Post-operative images. a. Extra-oral images.**



**Fig. 4 Post-operative images, b. Intra-oral images**



**Fig. 5- Post orthodontic treatment radiographs**

## 7. Discussion

In clinical dentistry, PAOO is a new and uncharted territory. The majority of the growing body of evidence of PAOO comes from case-control and observational research.<sup>7</sup> In the majority of cases requiring orthodontic treatment, PAOO can be used to accelerate tooth movement. It has been demonstrated to be very successful in treating mild to moderate crowding, Class II skeletal or dental malocclusions needing expansion or extractions, and spacing with class II skeletal bases.<sup>8</sup>

In the present case, the patient had a class I malocclusion with bimaxillary dento-alveolar protrusion and spacing in upper and lower anteriors. PAOO was employed along-with fixed orthodontic therapy to speed-up the tooth movement. Patient had tongue thrusting habit as well which was managed with a fixed palatal crib.

One of the major advantages of PAOO technique is that it has not been associated with any serious negative effects. It is safe, highly predictable, associated with lesser root resorption, and shorter treatment times.<sup>9,10,11</sup>

The effects and mechanisms of this treatment were outlined by recent, well-designed histological studies.<sup>12</sup> Regional Acceleratory Phenomenon (RAP) is a limited and temporal osteoporosis-like/increased bone turnover state that has been linked to the rapid tooth movement and stability caused by PAOO.<sup>13</sup>

RAP is a natural occurrence during the bone-healing process that typically occurs after a fracture, osteotomy, and/or grafting. Therefore, the PAOO technique entails the activation and recruitment of

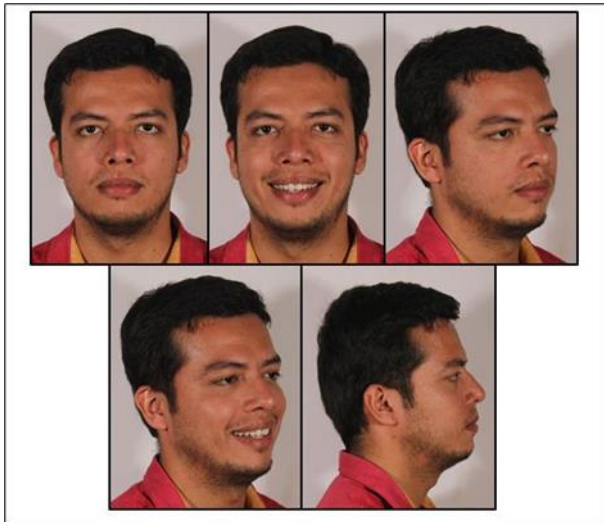precursor cells into the injured/wounded location, resulting in a subsequent two to ten-fold boosts in hard and soft tissue healing.<sup>14</sup>

The five steps of the surgical procedure performed for PAOO in the present case were, flap reflection, decortication, particle grafting, closure, and application of orthodontic force.<sup>15</sup> Corticotomy helps to alleviate some of the drawbacks of conventional orthodontic therapy, including the lengthy duration required, the constrained range of motion, and the challenge of performing motions in certain directions. The following are some of the applications of PAOO: eliminate crowding and shorten treatment time, hasten canine retraction after premolar extraction, anchorage manipulation, boost post-orthodontic stability, promote impacted tooth eruption, correction of molar intrusion.<sup>16</sup>

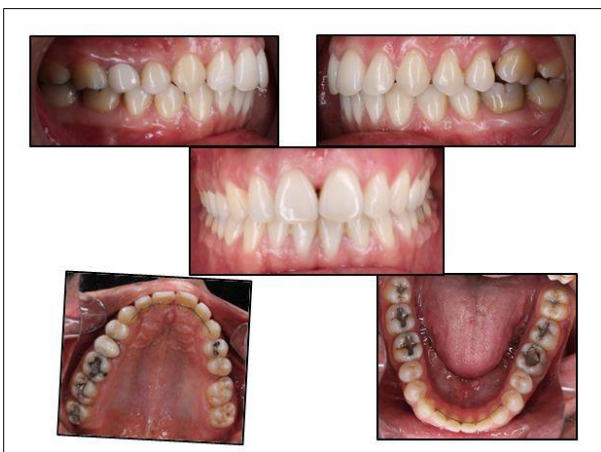One of the very few systematic reviews on PAOO was performed by Alsino H and co-workers in 2022.<sup>17</sup> It was observed that, in comparison to traditional orthodontic treatment, the PAOO sped up the leveling and alignment stage from 39% to 47% and the retraction of the upper anterior teeth from 41% to 61%. Only one study found that PAOO, used as an adjuvant therapy, decreased treatment time by 30.3% when compared to corticotomy alone.<sup>17</sup>

In the present case, the results were favourable and showcased the following outcome- Proclination and spacing along with rotations of affected teeth was corrected. Retraction & uprighting of incisors and closure of all spaces was observed. Habit correction w.r.t. tongue thrusting resulted in improved facial profile and lip competency. The required time for orthodontic treatment was one year and space closure was accomplished in two months after PAOO. The patient was kept under regular follow-up regime for five years (Fig 6.a,b) and showed fantastic rate of healing and stability of periodontium.





**Fig. 6. Five year follow-up images. a. Extra-oral images.**



**Fig. 6. Five year follow-up images, b. Intra-oral images**

Hence, to fully utilize the potential of this technique, accurate treatment planning is crucial. This method belongs in the realm of research and clinical practice where Periodontists and Orthodontists collaborate on every stage of care, from diagnosis to retention.

## 8. Conclusion

The PAOO procedure is gaining popularity with patients and doctors because of the much shorter treatment times and the increased range of treatment capabilities and possibilities. The presented case successfully demonstrated that tooth movement can be enhanced and cases can be completed with increased

alveolar volume using PAOO in carefully selected patients.

## Declaration of patient consent

The authors certify that they have obtained all appropriate patient consent forms. In the form, the patient has given his consent for his images and other clinical information to be reported in the journal. The patients understands that his names and initials will not be published and due efforts will be made to conceal his identity, but anonymity cannot be guaranteed.

## Financial support and sponsorship

Nil.

## Conflicts of interest

There are no conflicts of interest.

## References

1. Einy S, Horwitz J, Aizenbud D. Wilckodontics— an alternative adult orthodontic treatment method: rationale and application. *Alpha Omegan*. 2012;104:102-11.
2. Kole H. Surgical operations on the alveolar ridge to correct occlusal abnormalities. *Oral Surg Oral Med Oral Pathol*. 1959;12(3):277-88 .
3. Goyal A, Kalra JPS, Bhatiya P, Singla S, Bansal P. Periodontally accelerated osteogenic orthodontics (PAOO) - a review. *J Clin Exp Dent*. 2012;e292-6.
4. Wilcko WM, Wilcko T, Bouquot JE, Ferguson DJ. Rapid orthodontics with alveolar reshaping: two case reports of decrowding. *Int J Periodontics Restorative Dent*. 2001;21:9-19
5. Ferguson DJ, Wilcko MT, Wilcko WM, Makki L. Scope of treatment with periodontally accelerated osteogenic orthodontics therapy. *Semin Orthod*. 2015;21:176-86.
6. Fariña R, Salinas F, Zurbuchen A, Hinojosa A, Barreda M. Corticotomy-Assisted Le Fort I Osteotomy: An Alternative to Segmentation of the Maxilla in Orthognathic Surgery. *J Craniofac Surg*. 2015;26(13):16-20
7. Muñoz F, Jiménez C, Espinoza D, Vervelle A, Beugnet J, Haidar Z. Use of leukocyte and



- platelet-rich fibrin (L-PRF) in periodontally accelerated osteogenic orthodontics (PAOO): Clinical effects on edema and pain. *J Clin Exp Dent*. 2016;8(2):e119-24.
8. Dibart S, Sebaoun JD, Surmenian J. Piezocision: a minimally invasive, periodontally accelerated orthodontic tooth movement procedure. *Compend Contin Educ Dent*. 2009;30:342-4, 346, 348-50.
  9. Fischer TJ. Orthodontic treatment acceleration with corticotomy assisted exposure of palatally impacted canines. *Angle Orthod*. 2007;77:417-20.
  10. Lee JK, Chung KR, Baek SH. Treatment outcomes of orthodontic treatment, corticotomy-assisted orthodontic treatment, and anterior segmental osteotomy for bimaxillary dentoalveolar protrusion. *Plast Reconstr Surg*. 2007;120:1027-36.
  11. Oztürk M, Doruk C, Ozec I, Polat S, Babacan H, Bicakci AA. Pulpal blood flow: effects of corticotomy and midline osteotomy in surgically assisted rapid palatal expansion. *J Craniomaxillofac Surg*. 2003;31:97-100.
  12. Karanth S, Ramesh A, Thomas B, John AM. Periodontally accelerated osteogenic orthodontics: Review on a surgical technique and a case report. *J Interdiscip Dentistry*. 2012;2:179-84.
  13. Addanki P, Gooty JR, Palaparthi R. periodontally accelerated osteogenic orthodontics (PAOO) - an updated literature review and recent advances. *Natl J Integr Res Med*. 2016; 7(4): 140-146.
  14. Shih MS, Norrdin RW. Regional acceleration of remodeling during healing of bone defects in beagles of various ages. *Bone*. 1985;6:377-9
  15. Murphy KG, Wilcko MT, Wilcko WM, Ferguson DJ. Periodontal accelerated osteogenic orthodontics: a description of the surgical technique. *J Oral Maxillofac Surg*. 2009;67:2160-6.
  16. Kim SH, Kim I, Jeong DM, Chung KR, Zadeh H. Corticotomy assisted decompensation for augmentation of the mandibular anterior ridge. *Am J Orthod Dentofacial Orthop*. 2011;140:720-31.
  17. Alsino H, Hajeer M, Burhan A, Alkhouri I, Darwich K. The Effectiveness of Periodontally Accelerated Osteogenic Orthodontics (PAOO) in Accelerating Tooth Movement and Supporting Alveolar Bone Thickness During Orthodontic Treatment: A Systematic Review. *Cureus*. 2022;14(5):e24985.