



Management of Immediate Post-Arrest Lower Segment Cesarean Section in a 25-Year-Old with Previous LSCS: A Case Report

Dr. Bharat Krishna M^{1*}, Dr. Mannuru Harish², Dr. Niranjana D³, Dr. Subaskaran D⁴

¹Postgraduate, Department of Anesthesiology, Saveetha Medical College, Chennai

²Postgraduate, Department of Anesthesiology, Stanley Medical College, Chennai

³Professor and Head, Department of Anesthesiology, Thiruvallur Government Medical College Hospital, Thiruvallur

⁴Junior Resident, Department of Anesthesiology, Thiruvallur Government Medical College Hospital, Thiruvallur

*Corresponding author:

Dr Bharat Krishna M, Postgraduate, Department of Anesthesiology, Saveetha Medical College, Chennai

(Received: 07 October 2023

Revised: 12 November

Accepted: 06 December)

KEYWORDS

LSCS,
pregnancy,
maternal, foetal,
prognosis

ABSTRACT:

Immediate Post-Arrest Lower Segment Caesarean Section (LSCS) is a serious circumstance that must be managed quickly and efficiently to guarantee the mother's and fetus's well-being. This emergency situation occurs when a pregnant woman has a cardiac arrest, prompting rapid delivery to enhance maternal and foetal prognosis. This case report details the effective care of an immediate post-arrest LSCS in a 25-year-old prenatal woman at 38 weeks and 2 days gestation who had previously had an LSCS. The patient was in labour with breech presentation with draining PV. Following a sudden cardiac arrest during preoperative preparation for an emergency LSCS, a multidisciplinary strategy comprising obstetric, anaesthetic, and neonatal teams was critical in ensuring a favourable result for both mother and baby.

1. Introduction

Immediate Post-Arrest Lower Segment Cesarean Section (LSCS) is a critical situation that requires prompt and efficient management to ensure the well-being of both the mother and the fetus. (1) Fetal delivery boosts maternal cardiac output by 60-80%. Immediate delivery is crucial during maternal cardiac arrest, optimizing outcomes for both mother and fetus. (2) In such cases, a multidisciplinary approach involving obstetricians, anesthesiologists, neonatologists, and critical care specialists is crucial for successful management.

The first step in managing a case of immediate post-arrest LSCS is a rapid and coordinated response. Healthcare providers should be trained to recognize signs of cardiac arrest and initiate Basic Life Support (BLS) procedures immediately. Timely cardiopulmonary resuscitation (CPR) is crucial to maintaining oxygenation and perfusion to vital organs, including the fetus. (3) The obstetric team should be

alerted promptly to prepare for the emergent delivery. Once the mother is stabilized with BLS, advanced airway management should be initiated. Intubation by experienced anesthesiologists is preferred, and careful attention should be given to prevent complications such as aspiration. (3) Maintaining optimum oxygenation is vital for foetal well-being during the critical period preceding the caesarean section. Effective communication and coordination with the obstetric team are critical for addressing immediate post-arrest LSCS. The choice to perform an emergency caesarean section is based on gestational age, foetal well-being, and mother stability. The obstetric team must be prepared to execute the caesarean section quickly, with little delay.

Anaesthesia management in these circumstances should prioritise maternal hemodynamic stability while limiting foetal exposure to anaesthetic drugs. General anaesthesia is frequently recommended because to its speedy induction and delivery. However, the choice of anaesthetic procedure might vary according on the



circumstances and the patient's clinical state. (5) Simultaneously, the neonatal team should be prepared to resuscitate the newborn immediately after delivery. Anticipation of potential complications, such as meconium aspiration or prematurity, is crucial. The neonatologist should be ready to provide advanced neonatal resuscitation measures and intensive care support. Following successful delivery, postoperative care focuses on stabilizing the mother and closely monitoring both maternal and neonatal outcomes. Continuous hemodynamic monitoring, adequate pain management, and intensive care support may be required for the mother. The neonate may need admission to the neonatal intensive care unit (NICU) for further evaluation and management.

Maternal cardiac arrest during pregnancy is a complex and difficult circumstance that need prompt and deliberate action to guarantee the survival of both the mother and the foetus. One such severe condition is the immediate post-arrest Lower Segment Caesarean Section (LSCS), a life-saving treatment developed to meet emergent situations in which the woman goes into cardiac arrest during the prenatal period. This study focuses on the care of an immediate post-arrest LSCS in a 25-year-old gravida 2 para 1 (G2P1L1) patient with a prior LSCS.

This case report aims to provide a detailed account of the multidisciplinary approach used to manage the immediate post-arrest LSCS in a 25-year-old gravida 2 para 1 patient, shedding light on the critical decisions, intraoperative interventions, and postoperative care strategies that contributed to a positive outcome for both the mother and the neonate. The insights gained from this case not only contribute to the expanding body of information on obstetric crises, but also emphasise the need of readiness, coordination, and prompt interventions in optimising outcomes in high-risk mother settings.

Case Presentation

The patient, a 25-year-old antenatal woman at 38 weeks and 2 days of gestation, with an obstetric score of G2P1L1 and a history of a previous LSCS, presented to the emergency room in labor. The fetus was in breech presentation, and the patient experienced PV draining. Fetal movements were well-perceived, and no other

investigation reports were available.

Preoperative Phase:

During preoperative preparation for an emergency LSCS, the patient suddenly became unresponsive. The anesthesiologists were called, and immediate CPR was initiated. After two cycles of CPR and 1mg Inj Adrenaline IV, return of spontaneous circulation (ROSC) was achieved. Post-ROSC vital signs included a heart rate of 126/min and a blood pressure of 90/50mmHg. The decision to proceed with LSCS was made, and the patient was swiftly shifted to the operating room.

Intraoperative Management:

Monitors were applied, and general anesthesia was induced with Inj Glyco 0.2mg IV, Inj Ketamine 80mg IV, and Inj Suxa 100mg IV. Intubation was performed using a size 7 cuffed ETT with a size 4 Macintosh DL. Maintenance included Sevoflurane 2% and Atracurium 0.1mg/kg. Central line placement via the right IJV and initiation of Inj Noradrenaline infusion at 0.025mcg/kg/min were performed. Intraoperatively, 2 units PRBC and 2 units FFP were transfused. Postoperatively, the patient was shifted to the ICU with ETT in situ for elective ventilation.

Postoperative Phase:

In the ICU, CBC and RFT were repeated. ECHO showed EF: 50%, Mild MR, Mild TR, and No RWMA. All lab investigations were within the normal range. The patient was successfully extubated on POD 1 and discharged on POD 5.

Peripartum Considerations in CPR:

Maternal cardiac arrest teams, including adult resuscitation, obstetrics, anesthesia care providers, and neonatology teams, were involved. Aorticaval compression, hand positioning, defibrillation issues during pregnancy, and attention to airway and breathing were key considerations.

PMCD:

Perimortem cesarean delivery (PMCD) was defined as the birth of the fetus after maternal cardiac arrest. It was planned when manual left uterine displacement was insufficient to improve hemodynamics. The purpose of timely PMCD was to facilitate resuscitation and ensure early delivery of the baby.



Systolic BP	
<80	3
80–89	2
91–139	0
140–149	1
150–159	2
>160	3

Respiratory rate	
<10	3
10–17	0
18–24	1
25–29	2
>30	3

Heart rate	
<60	3
60–110	0
111–149	2
>150	3

FiO₂ to keep Sat >96%	
Room air	0
24%–39%	1
>40%	3

Temperature	
<34	3
34.1–35.0	1
35.1–37.9	0
38.0–38.9	1
>39.0	3

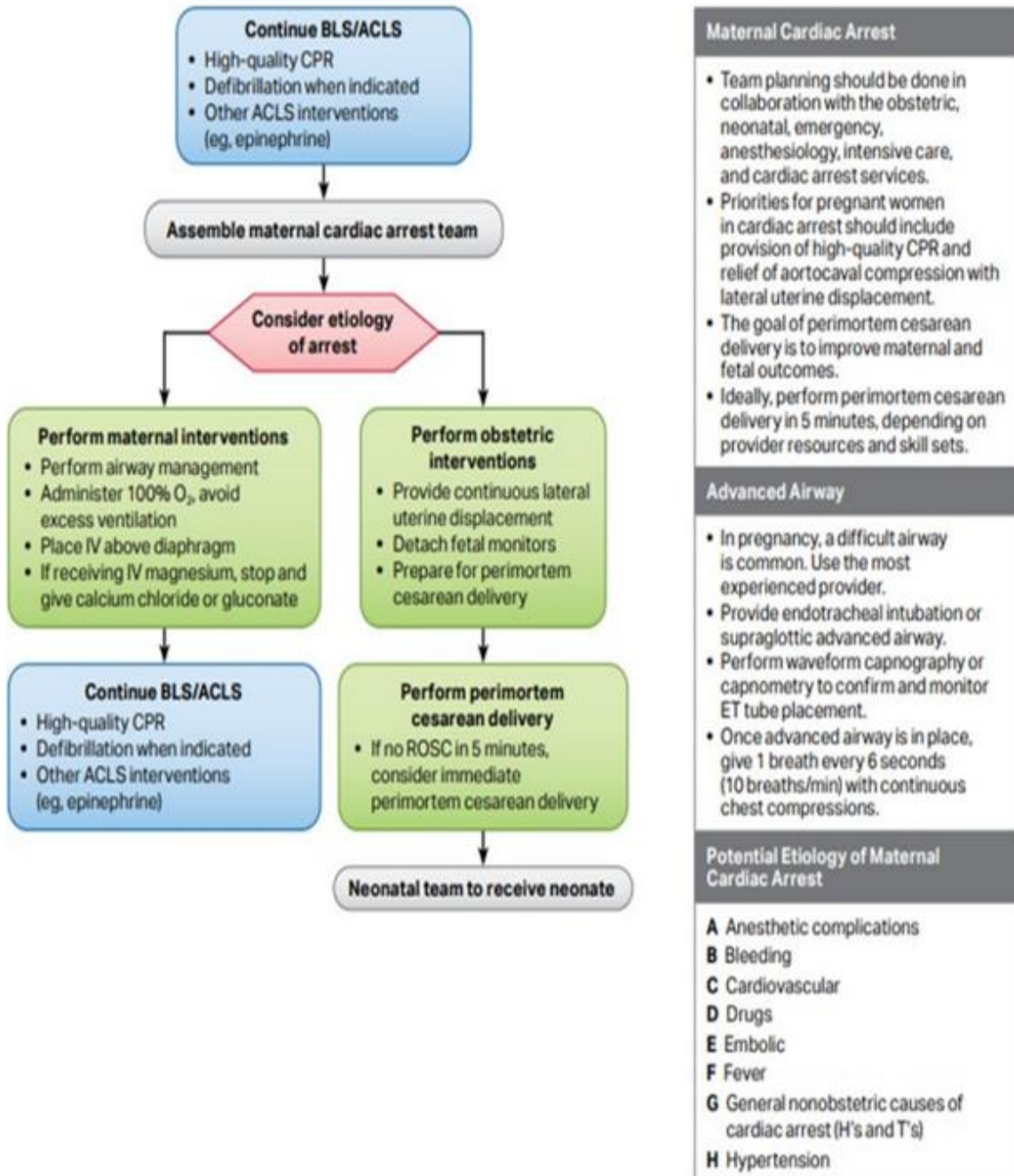
Consciousness	
Alert (GCS=15)	0
Not alert (<15)	3

Figure A: Color-Coded Early Warning Score Chart for Vital Signs Monitoring in Pregnancy: Based on Carle et al. Scoring System



Figure B: In-Hospital Advanced Cardiovascular Life Support (ACLS) Algorithm for Cardiac Arrest During Pregnancy

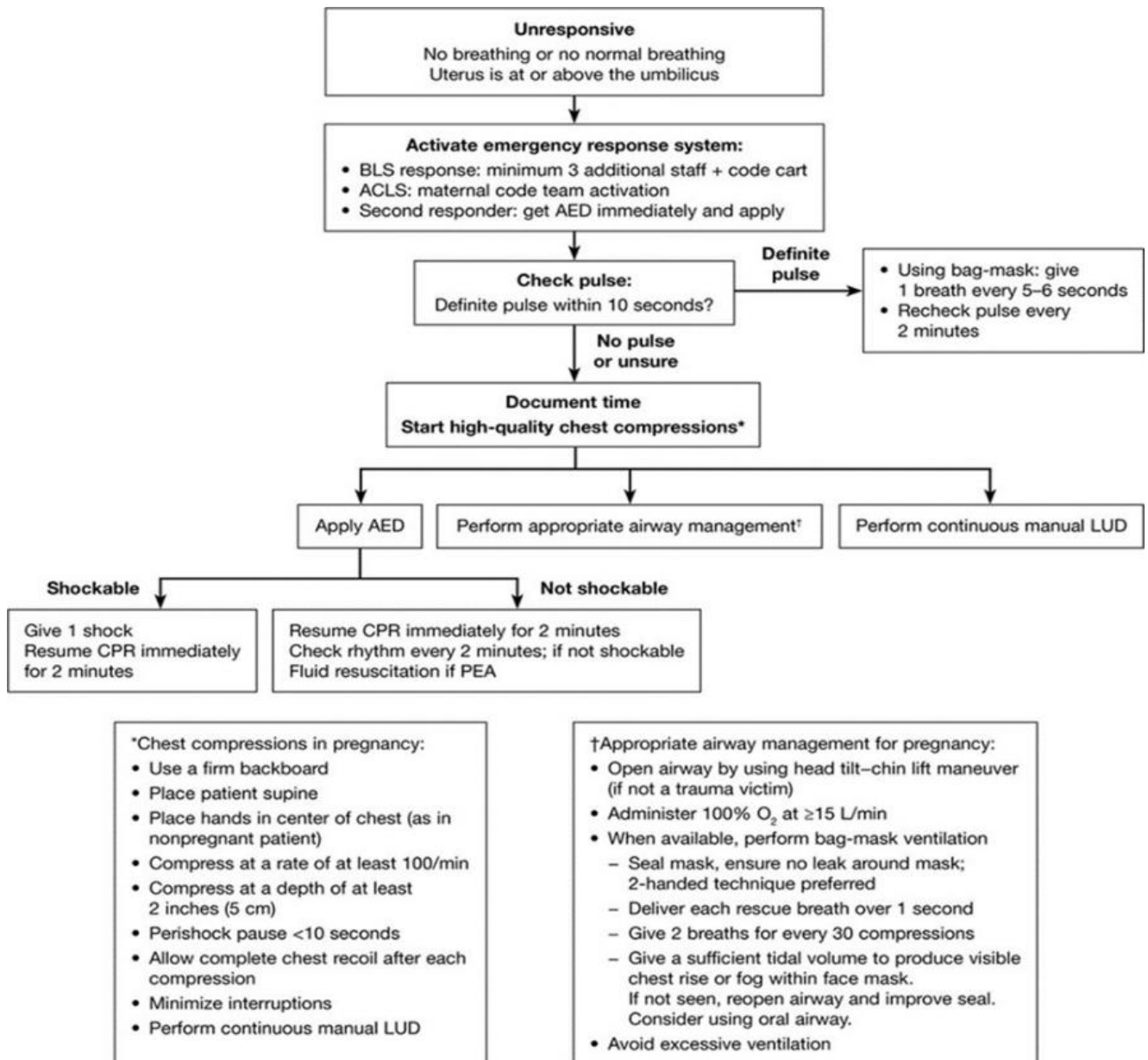
Cardiac Arrest in Pregnancy In-Hospital ACLS Algorithm



Source: Cardiac Arrest in Pregnancy In-Hospital ACLS Algorithm
https://cpr.heart.org/-/media/CPR-Files/CPR-Guidelines-Files/Algorithms/AlgorithmACLS_CA_in_Pregnancy_InHospital_200612.pdf



Figure C: In-Hospital Basic Life Support Algorithm for Cardiac Arrest in Pregnancy: Simultaneous C-A-B-U Approach



Source: <https://www.ahajournals.org/doi/10.1161/CIR.000000000000300>

2. Discussion

The management of immediate post-arrest Lower Segment Cesarean Section (LSCS) in a 25-year-old pregnant woman with obstetric score gravida 2 para 1 with a history of a previous LSCS presents a complex and challenging clinical scenario that requires a comprehensive multidisciplinary approach. This discussion aims to delve into the key aspects of this

case, including the challenges faced during preoperative preparation, intraoperative management, and postoperative care, highlighting the critical decisions and interventions that contributed to the positive outcome for both the mother and the neonate.

Preoperative Challenges:

The patient's entrance in the emergency room with a breech presentation and draining per vaginum (PV)



highlighted the urgency. The preceding caesarean section complicated the choice for an emergency LSCS, necessitating the contemplation of a repeat caesarean delivery. The unexpected heart arrest during preoperative preparation required rapid and effective cardiopulmonary resuscitation (CPR). The successful restoration of spontaneous circulation (ROSC) enabled the following choice to proceed with immediate post-arrest LSCS. Preoperative problems highlight the significance of recognizing deteriorating maternal health swiftly, professional resuscitation attempts, and timely decision-making in urgent obstetric scenarios.

The study “Cardiac arrest during pregnancy: ongoing clinical conundrum” highlights the increasing maternal mortality rate in the United States, despite global improvement. Socioeconomic and clinical factors contribute to this complexity, emphasizing the importance of clinician preparedness in managing maternal cardiac arrest. The interdisciplinary approach, familiarity with pregnancy-related physiological changes, and timely interventions are crucial. The study recommends mitigating obstacles, performing high-quality chest compressions, and considering perimortem delivery if standard resuscitation fails. Simulation and team training enhance readiness, but knowledge gaps persist, requiring further research for optimal maternal resuscitation. (6)

In the review “Cardiac interventions in pregnancy and peripartum,” the UK's maternal mortality rate and heart disease's leading role in non-obstetric maternal deaths are highlighted. Congenital heart disease (CHD) becomes prevalent, requiring cardiac interventions during pregnancy. Adaptive cardiovascular changes in pregnant women may lead to cardiovascular collapse, necessitating interventions like percutaneous endovascular procedures or cardiac surgery. The study emphasizes the importance of understanding maternal physiology and fetomaternal perfusion for successful cardiac intervention management. (7)

“The Society for Obstetric Anaesthesia and Perinatology Consensus Statement on the Management of Cardiac Arrest in Pregnancy was created to improve maternal resuscitation. It focuses on education, behavioral/communication tactics, system failures, and regular performance evaluations. The statement includes crucial information and protocols for dealing with issues during real occurrences. It focuses on problematic portions of the American Heart Association 2010 recommendations, with the purpose of improving

maternal outcomes in cardiac arrest circumstances during pregnancy”. (8)

Intraoperative Management:

The success of this case hinged on the pivotal role played during the intraoperative phase. The decision to induce general anesthesia and the selection of anesthetic agents were influenced by the imperative for swift and controlled delivery. Intubation using a cuffed endotracheal tube (ETT) facilitated secure airway management, ensuring effective ventilation. Utilizing Sevoflurane and Atracurium for maintenance achieved maternal unconsciousness and muscle relaxation while minimizing fetal exposure to anesthetic agents. Hemodynamic stability was meticulously maintained with the initiation of noradrenaline infusion, reflecting a judicious approach to maternal resuscitation. Central line placement via the right internal jugular vein (IJV) provided reliable vascular access for fluid administration and hemodynamic monitoring. Administration of packed red blood cells (PRBC) and fresh frozen plasma (FFP) intraoperatively addressed potential blood loss, maintaining maternal hemostasis. The complexities arising from a previous LSCS underscore the critical role of a proficient obstetric and anesthesia team in navigating emergent cesarean sections.

According to the article “Anaesthetic Management of Nonobstetric Surgery during Pregnancy,” nonurgent surgery during pregnancy necessitates careful planning, including optimal timing, intraoperative foetal monitoring, and anaesthetic technique modifications. Recent developments include the greater use of laparoscopic methods, as well as a better grasp of pain management and maternal cardiac resuscitation. Traditional ideas concerning aspiration prophylaxis, worries about abortifacient and teratogenic qualities, and diagnostic imaging during pregnancy have been reassessed. To guarantee the best possible results, urgent and emergent procedures during pregnancy should be performed right away. Anaesthetic treatment may require adaptations to account for physiological changes, with an emphasis on preserving uteroplacental perfusion.” (9)

Another research. “Clinical practice recommendations on the management of perioperative cardiac arrest: A report from the PERIOPCA Consortium” discusses the rarity of perioperative cardiac arrest and its high fatality rate. The PERIOPCA Task Force developed questions and conducted systematic literature reviews till



September 2020. The GRADE method was used to provide consensus-based recommendations. Despite limits in data, these suggestions serve as a foundation for decision-making and lead future research on perioperative cardiac arrest, generating insights for healthcare practitioners". (10)

Postoperative Care:

The transition to postoperative care, with the patient being transferred to the Intensive Care Unit (ICU) for elective ventilation, was critical in ensuring long-term maternal and newborn stability. Repeated laboratory tests, including a complete blood count (CBC) and renal function tests (RFT), supplied information on the patient's postoperative recovery. Echocardiography data, such as ejection fraction (EF) and valve function, directed continuing care and identified prospective cardiac problems. Extubation on surgical day one, followed by a favourable discharge on postoperative day five, indicating that the postoperative care approach was successful. The absence of problems, both maternal and neonatal, emphasises the success of the interdisciplinary strategy used in this instance. The peripartum period requires a specialized approach to cardiopulmonary resuscitation (CPR), involving a maternal cardiac arrest team that includes adult resuscitation, obstetric, anesthesia care providers, and neonatology teams. Aortocaval compression, hand positioning, and the consideration of defibrillation issues during pregnancy were critical components in ensuring effective CPR while prioritizing fetal well-being.

The concept of perimortem cesarean delivery (PMCD) becomes particularly relevant in cases of maternal cardiac arrest, where the primary goals are to facilitate resuscitation and ensure the timely delivery of the baby. When manual left uterine displacement is insufficient to improve hemodynamics, PMCD becomes a planned intervention, emphasizing the dual purpose of aiding resuscitation efforts and expediting fetal delivery.

Research insight:

It is critical to explore and analyse this case within the larger framework of current literature in order to acquire a thorough knowledge of the obstacles and effective tactics used in comparable instances. The research "Out-of-hospital cardiac arrest in pregnancy with good neurological outcome for mother and infant" emphasises the rarity of cardiac arrest during pregnancy, particularly when it occurs outside of the hospital. Resuscitation in these circumstances presents

particular problems due to changed physiology, specialised diseases, and the presence of the foetus. The lack of high-quality evidence for post-resuscitation care hinders decision-making. The highlighted example, which demonstrates successful resuscitation and favourable neurological results, emphasises the need of educated decision-making, effective resuscitation, and continued education in treating such crucial situations. (11)

The second research, "Maternal cardiac arrest in early pregnancy, describes a primigravid lady who suffered a protracted cardiac arrest at 18 weeks of gestation. The discussion focuses on the diagnosis of dilated ischemic cardiomyopathy, subsequent recovery, and an elective caesarean birth at 38 weeks with positive results for both mother and child. This study emphasises the role of pregnancy in underlying heart illness and the importance of a multidisciplinary approach. Furthermore, it emphasises the need for ongoing neurodevelopmental assessments of the infant to detect potential long-term consequences of foetal hypoxia." (12)

The third research, "Intensive Care Management of the Pregnant Patient after Cardiac Arrest, recognises the rarity of cardiac arrest in pregnancy, resulting in limited intensivists expertise in post-cardiac arrest care during pregnancy. The research calls for pregnancy-specific intensive care, with a focus on cardiac arrest and resuscitation. It emphasises the need of setting temperature, hemodynamic, oxygenation, ventilation, and sedation objectives that are consistent with general guidelines. The study emphasises the necessity for a multimodal prognostication method in situations of prolonged unconsciousness." (13) the fourth study, "Cardiac arrest in a case of undiagnosed dilated cardiomyopathy patient presenting for emergency caesarean section, describes a difficult scenario in which an undiagnosed dilated cardiomyopathy patient suffers severe ventricular arrhythmias and cardiac arrest during an emergency caesarean section. The example emphasises the difficulty faced by asymptomatic gestation and the significance of collecting a thorough patient history to determine proper care." (14)

Finally, the research "Case report: Maternal cardiac arrest at 12 hours postpartum investigates a rare incidence of maternal cardiac arrest in a woman with preeclampsia. The study dives into advanced cardiac life support procedures used to restore spontaneous circulation, such as chest compressions. It gives insights



into the underlying reasons contributing to cardiac arrest during the postpartum period and emphasises the successful tactics used by the multidisciplinary team to manage this crucial medical event.” (15)

3. Conclusion

This case report underscores the complexities and challenges associated with the management of immediate post-arrest LSCS in a high-risk obstetric patient. The successful outcome in this case was attributed to a well-coordinated and prompt multidisciplinary approach involving obstetricians, anesthesiologists, and neonatologists. The challenges faced during the preoperative, intraoperative, and postoperative phases highlight the critical importance of preparedness, rapid decision-making, and effective communication in navigating emergent obstetric scenarios.

While maternal cardiac arrest is a rare occurrence, its increasing frequency emphasizes the need for a standardized and specialized approach to resuscitation in pregnant patients. The utilization of basic life support (BLS) and advanced cardiac life support (ACLS) algorithms, coupled with considerations for PMCD, hand positioning, and defibrillation, should form the backbone of the response plan to maternal cardiac arrest. This case contributes valuable insights to the existing literature, emphasizing the importance of continuous education, training, and protocol development to enhance healthcare teams' readiness to manage such critical obstetric emergencies.

Acknowledgments:

The surgical and medical teams involved in the treatment of these individuals are acknowledged by the authors for their tireless efforts.

Conflict of Interest:

The authors declare no conflicts of interest.

Informed Consent:

Informed consent was obtained from patient for the publication of their case details and associated images.

References

1. van Liempt SW, Stoecklein K, Tjong MY, Schwarte LA, de Groot CJ, Teunissen PW. Essentials in cardiac arrest during cesarean

- section. *Clin Pract.* 2015 Feb 17;5(1):668.
2. Hill CC, Pickinpaugh J. Trauma and surgical emergencies in the obstetric patient. *Surg Clin North Am.* 2008 Apr;88(2):421-40, viii.
3. Curran CA. Perianesthesia care following obstetric emergencies at risk for multisystem organ dysfunction. *Journal of PeriAnesthesia Nursing.* 2005 Jun;20(3):185-99.
4. Whitty JE. Maternal cardiac arrest in pregnancy. *Clin Obstet Gynecol.* 2002 Jun;45(2):377-92.
5. Prior, C. H., Burlinson, C. E. G., & Chau, A. (2022). Emergencies in obstetric anaesthesia: a narrative review. *Anaesthesia*, 77(12), 1416-1429. <https://doi.org/10.1111/anae.15839>.
6. Zelop CM, Einav S, Mhyre JM, Martin S. Cardiac arrest during pregnancy: ongoing clinical conundrum. *American journal of obstetrics and gynecology.* 2018 Jul 1;219(1):52-61.
7. Carlier L, Devroe S, Budts W, Van Calsteren K, Rega F, Van de Velde M, Rex S. Cardiac interventions in pregnancy and peripartum—a narrative review of the literature. *Journal of Cardiothoracic and Vascular Anesthesia.* 2020 Dec 1;34(12):3409-19.
8. Lipman S, Cohen S, Einav S, Jeejeebhoy F, Mhyre JM, Morrison LJ, Katz V, Tsen LC, Daniels K, Halamek LP, Suresh MS, Arafah J, Gauthier D, Carvalho JC, Druzin M, Carvalho B; Society for Obstetric Anesthesia and Perinatology. The Society for Obstetric Anesthesia and Perinatology consensus statement on the management of cardiac arrest in pregnancy. *Anesth Analg.* 2014 May;118(5):1003-16.
9. d'Arby Toledano R, Madden HE, Leffert L. Anesthetic management of nonobstetric surgery during pregnancy. *Current Anesthesiology Reports.* 2019 Feb 19;9(1):31-8.
10. Chalkias A, Mongardon N, Boboshko V, Cerny V, Constant AL, De Roux Q, Finco G, Fumagalli F, Gkamprela E, Legriel S, Lomivorotov V, Magliocca A, Makaronis P, Mamais I, Mani I, Mavridis T, Mura P, Ristagno G, Sardo S, Papagiannakis N, Xanthos T; PERIOPCA Consortium. Clinical practice recommendations on the management of perioperative cardiac arrest: A report from the PERIOPCA Consortium. *Crit Care.* 2021 Jul 29;25(1):265.
11. Pecher S, Williams E. Out-of-hospital cardiac arrest in pregnancy with good neurological



- outcome for mother and infant. *International Journal of Obstetric Anesthesia*. 2017 Feb 1;29:81-4.
12. Nelissen EC, de Zwaan C, Marcus MA, Nijhuis JG. Maternal cardiac arrest in early pregnancy. *International Journal of Obstetric Anesthesia*. 2009 Jan 1;18(1):60-3.
 13. Skrifvars MB. Intensive Care Management of the Pregnant Patient after Cardiac Arrest. *Principles and Practice of Maternal Critical Care*. 2020:383-400.
 14. Bajwa SK, Bajwa SJ, Sood A. Cardiac arrest in a case of undiagnosed dilated cardiomyopathy patient presenting for emergency cesarean section. *Anesthesia, Essays and Researches*. 2010 Jul;4(2):115.
 15. Nivatpumin P, Lertkovit S. Case report: Maternal cardiac arrest at 12 hours postpartum. *Heliyon*. 2024 Jan 15;10(1).