



Dermoscopy in Topical Steroid-Dependent Face: A Cross-Sectional Study Evaluating Clinical Patterns and Associations with Duration and Potency of Steroid Use

Dr. Akshay Sharma,^{*1} Dr. Rajeev Agarwal,² Dr. Sharique Ali,³ Dr. Vivek Kumar,⁴ Dr. Neha Riyaz,⁵ Dr. Neha Bohra,⁶

1 – JR3, Department of Dermatology, Integral Institute of Medical Sciences and Research, Lucknow-226026, Uttar Pradesh, India

2- Prof. and Head, Department of Dermatology, Integral Institute of Medical Sciences and Research, Lucknow-226026, Uttar Pradesh, India

3- Professor – Department of Dermatology, Integral Institute of Medical Sciences and Research, Lucknow-226026, Uttar Pradesh, India

4- Assistant Professor – Department of Dermatology, Integral Institute of Medical Sciences and Research, Lucknow-226026, Uttar Pradesh, India

5- JR3, Department of Dermatology, Integral Institute of Medical Sciences and Research, Lucknow-226026, Uttar Pradesh, India

6 – JR3, Department of Dermatology, Integral Institute of Medical Sciences and Research, Lucknow-226026, Uttar Pradesh, India

*Corresponding Author

Dr. Akshay Sharma (JR3), Department of Dermatology, Integral Institute of Medical Sciences and Research, Lucknow-226026, Uttar Pradesh, India

(Received: 05 December 2025

Revised: 15 January 2026

Accepted: 10 February 2026)

KEYWORDS

Topical steroid-dependent face;
Dermoscopy;
Topical corticosteroids;
Facial dermatoses;
Steroid misuse

Abstract

Background: Topical steroid-dependent or damaged face (TSDF) is an increasingly recognized consequence of inappropriate and prolonged use of topical corticosteroids on facial skin, particularly in developing countries with easy over-the-counter access. Early or subclinical disease is often difficult to diagnose clinically, leading to continued misuse and progression. Dermoscopy may aid in early detection by revealing characteristic vascular and pigmentary changes.

Objectives: To evaluate dermoscopic features in patients with TSDF and to assess their association with the duration and potency of topical corticosteroid use.

Methods: This observational cross-sectional study included 150 adults with clinically diagnosed TSDF attending a tertiary care dermatology outpatient department. Demographic details and corticosteroid use history were recorded. Dermoscopic examination was performed using polarized and non-polarized modes, and findings were analyzed according to gender, steroid potency, and duration of use (<6 months vs ≥6 months).

Results: Most patients were aged 20–30 years, with a female predominance (82%). Super-potent steroids were used by 48.7%, mainly for cosmetic indications. Common dermoscopic findings included brown globules (95.3%), red diffuse areas (92.7%), vascular patterns (86.7%), white structureless areas (87.3%), and hypertrichosis (80.7%). Several features, including serpentine, polygonal, and branched vessels, brown globules, white structureless areas, and red diffuse areas, were significantly associated with longer steroid use ($p < 0.001$), while potency showed no significant association.

Conclusion: Dermoscopy is a valuable adjunct in TSDF evaluation, with features correlating strongly with duration of steroid use, enabling earlier diagnosis and prevention of progressive facial damage.

Introduction



Topical corticosteroids remain among the most commonly prescribed yet frequently misused medications in dermatological practice due to their potent anti-inflammatory, antipruritic, and vasoconstrictive properties¹. These agents play a vital role in treating inflammatory dermatoses, but their irrational, prolonged, or unsupervised application—especially on the face—poses a growing clinical and public health challenge in India and other developing nations, with recent 2024-2025 studies confirming the persistence of misuse where potent steroids like mometasone and clobetasol dominate inappropriate prescriptions for conditions like seborrheic dermatitis and acne². Factors such as over-the-counter availability without stringent regulation, prescriptions from non-dermatologists or quacks, and the popularity of steroid-containing fixed-dose combinations marketed for fairness, acne, and pigmentation—often unapproved and combined with antifungals or antibiotics—exacerbate this epidemic, driving 78% of rural cases via easy access from pharmacists, non-qualified providers, or friends/relatives, while cultural demands for fair skin prompt prolonged use (>1 month) of agents like betamethasone despite guidelines limiting facial application to mild steroids for ≤ 2 weeks³. Clinically, this leads to erythema (42%), acneiform eruptions (22%), rosacea, hypertrichosis, atrophy, infections, and rebound symptoms fostering psychological dependence, with only 68.4% guideline adherence and rural-urban disparities complicating diagnosis of modified lesions like tinea incognita⁴.

Chronic topical corticosteroid application on facial skin causes topical steroid-dependent/damaged face (TSDF), marked by erythema (65.6%), hypertrichosis (62.4%), telangiectasia (51.2%), acneiform eruptions, burning, itching, atrophy, and pigmentary changes, with rebound flares and addiction on withdrawal. Facial vulnerability stems from thin epidermis (0.12 mm), high follicular density, and increased absorption. Despite growing awareness, 2024 studies note frequent underdiagnosis as rosacea or acne, perpetuating misuse^{4,5}.

Clinical examination remains the cornerstone for diagnosing TSDF, yet early subclinical changes often evade detection. Dermoscopy, a non-invasive tool visualizing epidermal and dermal structures, excels in inflammatory dermatoses by revealing vascular patterns

(linear, serpentine, polygonal, Y-shaped vessels in 71-90%), pigmentary shifts (brown globules 78%, red diffuse areas 94%), follicular alterations (Demodex tails, comedones), and atrophy (white structureless areas, pseudoreticular network breaks). 2024 studies affirm dermoscopy's adjunctive value, correlating findings with TCS duration/potency for earlier severity assessment than naked-eye exam⁶⁻⁸.

However, literature on dermoscopic patterns of TSDF remains limited, and data correlating these findings with the duration and potency of topical corticosteroid use are scarce. Understanding these associations is essential for early detection, prognostication, and patient counselling. In this context, the present study was undertaken to systematically evaluate dermoscopic features in patients with TSDF and to assess their relationship with the duration and potency of topical corticosteroid use. By elucidating characteristic dermoscopic patterns and their clinical correlations, this study aims to strengthen the role of dermoscopy in routine evaluation of TSDF and contribute to improved diagnostic accuracy and management strategies.

Materials and Methods

Study Design and Setting

This was an observational, cross-sectional study conducted in the outpatient department of Dermatology at Integral Institute of Medical Sciences and Research (IIMSR), Lucknow, a tertiary care teaching hospital. The study was carried out over a period of 18 months following approval from the Institutional Scientific Research Committee and the Institutional Ethics Committee. The study adhered to the principles outlined in the Declaration of Helsinki, and written informed consent was obtained from all participants prior to enrolment.

Study Population

Adult patients presenting to the dermatology outpatient department with clinical features suggestive of topical steroid-dependent or damaged face (TSDF) were screened for inclusion. Patients aged between 18 and 60 years with a history of topical corticosteroid application on the face for a duration of at least one month and exhibiting symptoms such as erythema, burning sensation, itching, swelling, acneiform eruptions,



pigmentation, striae, or photosensitivity were included in the study. Participation was voluntary, and only patients willing to provide informed consent were enrolled.

Patients with natural rosacea, pre-existing dermatological conditions that could mimic steroid-induced facial changes such as contact dermatitis, seborrheic dermatitis, or atopic dermatitis prior to steroid use were excluded. Individuals with systemic conditions resembling steroid adverse effects, including Cushing's syndrome, thyroid disorders, or polycystic ovarian syndrome, as well as those with a history of oral corticosteroid use for unrelated conditions, were excluded. Pregnant women were also excluded from the study.

Sampling Technique and Sample Size

A convenience sampling technique was employed. The sample size was calculated using the standard formula for estimating proportions, based on previously reported prevalence of dermoscopic features in TSDF. Assuming a prevalence of 90.5%, a confidence level of 95%, a margin of error of 5%, and accounting for a 10% non-response rate, the minimum required sample size was calculated to be 150 participants. All eligible patients presenting during the study period were consecutively recruited until the desired sample size was achieved.

Data Collection and Clinical Evaluation

A detailed history was obtained from each participant using a structured case record form. Information regarding age, gender, educational status, and chief complaints was recorded. A comprehensive history of topical corticosteroid use was elicited, including the indication for application, duration of use, frequency of application, type of steroid, and potency class. Additional details regarding past medical history, concomitant drug use within the preceding six months, facial hygiene practices, and cosmetic use were documented.

A thorough dermatological examination was performed in all patients, focusing on facial skin changes such as erythema, pigmentation, acneiform lesions, hypertrichosis, atrophy, scaling, and telangiectasia. Clinical findings were systematically recorded prior to dermoscopic evaluation.

Dermoscopic Evaluation

Dermoscopy was performed in all enrolled patients using a handheld dermoscope in both polarized and non-polarized modes. Dermoscopic examination was carried out over representative facial lesions without the application of immersion fluids to avoid compression artefacts. Images were captured using an iPhone 13 attached to a DermLite device and stored for analysis and documentation.

Dermoscopic features assessed included vascular patterns such as linear vessels, serpentine vessels, polygonal vessels, branched vessels, and Y-shaped vessels, as well as non-vascular features including red diffuse areas, brown globules, white structureless areas, white hair, hypertrichosis, desquamation, pustules, demodex tails, follicular plugging, comedones, and disruption of the pseudoreticular network. Dermoscopic findings were recorded independently of clinical findings to allow comparison between clinical and dermoscopic detectability.

Outcome Measures

The primary outcome measure was the frequency and pattern of dermoscopic features observed in patients with TSDF. Secondary outcome measures included the association of dermoscopic findings with duration of topical corticosteroid use and potency class of the steroid applied, as well as comparison of dermoscopic findings across gender groups.

Statistical Analysis

Data were entered into Microsoft Excel and analysed using the Statistical Package for Social Sciences (SPSS) software. Quantitative variables were expressed as mean \pm standard deviation, while qualitative variables were presented as frequencies and percentages. Associations between categorical variables were assessed using the Chi-square test or Fisher's exact test as appropriate. For comparison of dermoscopic findings based on duration of topical corticosteroid use, McNemar's test was employed. A p-value of less than 0.05 was considered statistically significant, and a p-value of less than 0.001 was considered highly significant.



Results:

1. Demographic and Clinical Profile of Study Participants

A total of 150 patients with clinically diagnosed topical steroid-dependent or damaged face were included in the analysis. The study population predominantly comprised young adults, with half of the participants belonging to the 20–30-year age group (50.0%). Females constituted a large majority of the cohort (82.0%). Redness was the most common presenting complaint, reported by nearly half of the patients (46.0%), followed by itching (25.3%). These findings indicate that TSDF predominantly affects young women and commonly presents with inflammatory facial symptoms (Table 1). Representative clinical and dermoscopic features of topical steroid-dependent face are shown in Figure 1.

Table 1. Demographic and clinical characteristics of study participants (n = 150).

Variable	Category	Frequency	Percentage (%)
Age group (years)	20–30	75	50.0
	31–40	46	30.7
	>40	29	19.3
Gender	Male	27	18.0
	Female	123	82.0
Education status	Illiterate	41	27.3
	High school	79	52.7
	Degree/Diploma	30	20.0
Chief complaint	Redness	69	46.0
	Itching	38	25.3
	Swelling	25	16.7
	Pigmentation	18	12.0

2. Pattern of Topical Corticosteroid Use

Nearly half of the patients reported the use of super-potent topical corticosteroids on the face (48.7%), while another 24.7% used high-potency formulations. More than half of the participants (56.7%) applied topical steroids daily. Cosmetic use for fairness was the most frequent indication, accounting for 60.7% of cases, highlighting

widespread non-therapeutic misuse of potent topical steroids (Table 2).

Table 2. Pattern of topical corticosteroid use among study participants.

Variable	Category	Frequency	Percentage (%)
Potency of steroid	Least	20	13.3
	Low	20	13.3
	High	37	24.7
	Super-potent	73	48.7
Frequency of application	Daily	85	56.7
	2–3 times/week	35	23.3
	Occasionally	30	20.0
Indication for use	Fairness	91	60.7
	Melasma	30	20.0
	General	29	19.3

3. Overall Dermoscopic Findings in TSDF

Dermoscopy revealed multiple vascular and non-vascular features in patients with TSDF. Brown globules were the most frequent finding, observed in more than 95% of patients, followed by red diffuse areas and various vascular patterns. White structureless areas and hypertrichosis were also commonly detected, often exceeding their clinical visibility, underscoring the role of dermoscopy in identifying subclinical changes (Table 3).

Table 3. Overall frequency of dermoscopic findings in topical steroid-dependent face.

Dermoscopic finding	Frequency	Percentage (%)
Brown globules	143	95.3
Red diffuse areas	139	92.7
Vascular patterns*	130	86.7
White structureless areas	131	87.3
Hypertrichosis	121	80.7
White hair	96	64.0



Desquamation	57	38.0
Pustules	46	30.7
Demodex tails	46	30.7
Follicular plugging	21	14.0
*Includes linear, serpentine, polygonal, branched, and Y-shaped vessels.		

4. Comparison of Dermoscopic Findings by Gender and Steroid Potency

Most dermoscopic features did not show statistically significant differences when compared across gender or steroid potency groups. Comedones were significantly more frequent in males than females (22.2% vs 7.3%, $p = 0.019$). Although features such as red diffuse areas, vascular patterns, and white structureless areas appeared numerically more common with increasing steroid potency, these differences were not statistically significant (all $p > 0.05$), suggesting that potency alone may not be a strong determinant of dermoscopic severity (Table 4).

Table 4. Comparison of dermoscopic findings by gender and potency of topical corticosteroid used.

Dermoscopic finding	Gender (p-value)	Potency (p-value)
Red diffuse areas	0.424	0.478
Vascular patterns	0.381	0.325
Hypertrichosis	0.614	0.661
Brown globules	0.204	0.585
White structureless areas	0.099	0.424
White hair	0.901	0.268
Desquamation	0.581	0.477
Pustules	0.210	0.831
Demodex tails	0.210	0.831
Follicular plugging	0.455	0.932
Comedones	0.019	0.364

5. Association of Dermoscopic Findings with Duration of Topical Steroid Use

Duration of topical corticosteroid use showed a strong association with several dermoscopic features. Patients with steroid use for ≥ 6 months demonstrated significantly higher frequencies of serpentine vessels, polygonal vessels, branched vessels, white structureless areas, brown globules, and red diffuse areas compared to those with < 6 months of use (all $p < 0.001$). Linear brown or red wavy streaks were also significantly associated with longer duration of use ($p = 0.011$). These findings indicate progressive dermoscopic changes with prolonged steroid exposure (Table 5).

Table 5. Association of dermoscopic findings with duration of topical corticosteroid use

Dermoscopic finding	< 6 months	≥ 6 months	p-value
Linear vessels (no branches)	32	42	0.245
Serpentine vessels	38	76	< 0.001
Polygonal vessels	12	39	< 0.001
Branched vessels	31	60	< 0.001
White structureless areas	39	89	< 0.001
Brown globules	39	99	< 0.001
Linear brown/red wavy streaks	14	30	0.011
Red diffuse areas	46	91	< 0.001
Follicular plugging	11	16	0.442
Demodex tails	18	30	0.073
Pustules	19	31	0.104

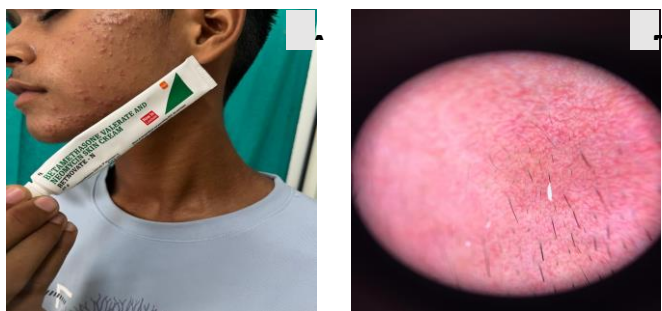


Fig 1: (A) 18-year-old boy presented with multiple erythematous papular lesions to which he applied betamethasone and neomycin cream.

(B) On dermoscopy, presence of erythema, linear telangiectasia, and Demodex tail.

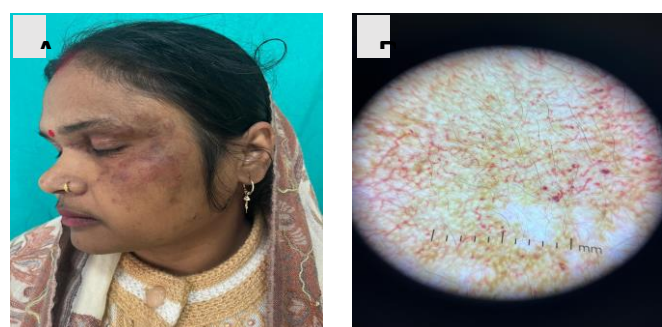


Fig 2: (A) 30 year old female complains of PIH and erythema over malar area to which she applied a potent topical steroid.

(B) On dermoscopy, presence of white globules interspersed with pigmentary network and branched and linear telangiectasia.

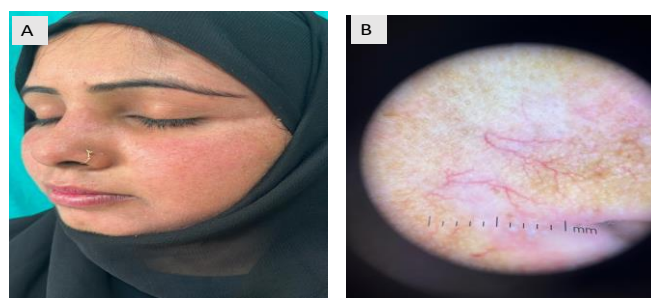


Fig 3: (A) shows 30 year old female complaining of erythema over bilateral cheek area and feeling of burning of skin.

(B) On dermoscopy there is presence of branched telangiectasia interspersed with brownish pigment and yellow globules.

Discussion

Our study evaluated 150 adults with topical steroid-dependent/damaged face and found that TSDF predominantly affects young women and is driven by cosmetic misuse of potent corticosteroids. Half of the cohort were 20–30 years old and 82 % were female, paralleling recent Indian reports. Goel et al. screened 250 TSDF patients and also found that women accounted for 83.2 % and most were 26–35 years old ⁹. Similarly, a hospital-based study

from Madhya Pradesh reported a mean age of 31.5 ± 8.13 years and a male-to-female ratio of 1:9 ¹⁰. In our series, the most frequent complaint was facial redness (46 %), followed by itching (25.3 %) and swelling (16.7 %), whereas the Indore cohort described redness in 82.5 % and itching in 66.3 % of patients. These variations likely reflect differences in patient perception and the stage of presentation. Nonetheless, the overall demographic pattern supports the notion that TSDF is an emerging public-health issue among young Indian women seeking fairness or melasma treatment. The high proportion of super-potent and high-potency steroid use in our cohort underscores easy over-the-counter availability and inadequate regulation of these agents.

Our primary objective was to characterize dermoscopic features in TSDF and to evaluate how dermoscopy complements clinical examination. The most consistent dermoscopic findings were brown globules (95.3 %), red diffuse areas (92.7 %), vascular patterns (86.7 %), white structureless areas (87.3 %) and hypertrichosis (80.7 %). These findings align closely with those reported by Sethi and colleagues, who documented brown globules in 96.2 % of patients, red diffuse areas in 92.4 %, vessels in 87.1 %, white structureless areas in 86.4 % and hypertrichosis in 80.3 % ¹¹. Another clinicodermoscopic study noted unpatterned brown pigmentation in 86.3 % and polygonal vessels in 73.8 % ¹⁰. The concordance between studies confirms that brown globules and red diffuse areas are hallmark features of TSDF. Brown globules likely correspond to melanin accumulation or hemosiderin deposition secondary to chronic inflammation and post-inflammatory hyperpigmentation. Red diffuse areas and various vascular patterns reflect persistent vasodilatation and telangiectasia; chronic topical steroid use suppresses cutaneous cortisol and nitric-oxide production, and withdrawal leads to rebound vasodilatation and erythema ^{12,13}. Serpentine, polygonal and branched vessels also indicate telangiectatic networks arising from repeated cycles of vasoconstriction and rebound. White structureless areas are markers of dermal atrophy;



glucocorticoids inhibit fibroblast proliferation, reduce mucopolysaccharides and elastin, and suppress collagen synthesis, resulting in a thinned dermis¹⁴. Hypertrichosis and white hairs were observed in 80.7% and 64% of our patients, respectively, probably due to androgenic effects of corticosteroids and follicular cycling disturbances. Our secondary objectives were to explore associations between dermoscopic patterns and the duration and potency of steroid use. Duration of use emerged as the key determinant: patients using steroids for ≥ 6 months showed significantly higher frequencies of serpentine vessels, polygonal vessels, branched vessels, white structureless areas, brown globules and red diffuse areas ($p < 0.001$). These findings indicate that vascular changes and dermal atrophy progress with prolonged exposure. Sethi et al. likewise reported that vascular patterns, red diffuse areas and pseudo-reticular network disruption were strongly associated with longer duration of steroid use¹⁵. Conversely, potency showed no significant correlation with most dermoscopic features in our study, despite nearly half of the participants using super-potent steroids. Goel et al. observed that only linear vessels, Demodex tails and comedones correlated with steroid potency, and another study reported no potency-related differences. These findings suggest that prolonged duration rather than potency per se drives the severity of dermoscopic damage; patients often switch between formulations or use lower-potency creams for longer periods, mitigating potency-specific effects. Gender did not influence most features, although comedones were more frequent in males ($p = 0.019$), potentially reflecting higher sebaceous activity. The absence of strong potency-related differences highlights the need for patient education on the dangers of chronic use of any topical steroid, regardless of class. The overall implications of our study are twofold. First, dermoscopy is a valuable non-invasive tool that detects early and subclinical TSDF changes, allowing clinicians to counsel patients before irreversible damage occurs. Our findings reaffirm that dermoscopy frequently reveals vascular and atrophic changes not appreciated clinically. Second,

the high prevalence of misuse and the strong correlation between duration of use and dermoscopic severity emphasize the importance of regulating over-the-counter sales of potent steroids and educating pharmacists and the public. Our study has limitations: the cross-sectional design precludes causal inferences; convenience sampling from a single tertiary centre limits generalizability; recall bias may affect estimates of steroid potency and duration; and histopathological correlation was not performed. We also did not assess psychological impact or quality-of-life measures, which have been shown to correlate with TSDF severity¹⁶. Nonetheless, our large sample, systematic dermoscopic documentation and robust statistical analysis provide valuable data for clinicians. Future studies should explore longitudinal changes after steroid withdrawal, incorporate quality-of-life assessments and evaluate the effectiveness of patient-education interventions. In summary, TSDF predominantly affects young women who misuse topical steroids for cosmetic purposes; dermoscopy reveals consistent patterns of brown globules, red diffuse areas, vascular networks and atrophy, which become more pronounced with prolonged use. Early recognition and intervention can mitigate damage and highlight the need for stricter regulation and public education.

Conclusion

This study demonstrates that dermoscopy is a useful adjunct in diagnosing topical steroid-dependent face, revealing characteristic vascular and pigmentary changes that correlate strongly with duration of steroid use. Early dermoscopic evaluation can facilitate timely intervention, patient counselling, and prevention of progressive and potentially irreversible facial skin damage.

Acknowledgement: Authors wish to acknowledge the Integral University, Lucknow for providing the manuscript communication number IU/R&D/2026-MCN0004330.

Funding Sources: Not applicable

Conflict of interest: None to declare



References:

1. Thomas M, Wong CC, Anderson P, Grills N. Magnitude, characteristics and consequences of topical steroid misuse in rural North India: an observational study among dermatology outpatients. *BMJ Open* [Internet]. 2020 May 1 [cited 2025 Dec 23];10(5):e032829. Available from: <https://bmjopen.bmj.com/content/10/5/e032829>
2. Coondoo A. Topical corticosteroid misuse: the Indian scenario. *Indian J Dermatol* [Internet]. 2014 Sep 1 [cited 2025 Dec 23];59(5):451–5. Available from: <https://pubmed.ncbi.nlm.nih.gov/25284848/>
3. Jhaj R, Asati D, Chaudhary D, Sadasivam B. Topical steroid containing combinations: Burden of adverse effects and why the recent regulatory action may not be enough. *Indian J Pharmacol* [Internet]. 2021 Sep 1 [cited 2025 Dec 23];53(5):371. Available from: <https://pmc.ncbi.nlm.nih.gov/articles/PMC8641741/>
4. S. SB, G. HN, K. SKA. Clinico-epidemiological study of topical steroid dependent face in a tertiary care hospital at Mysore. *Int J Basic Clin Pharmacol* [Internet]. 2020 Jun 26 [cited 2025 Dec 23];9(7):1073–8. Available from: <https://www.ijbcp.com/index.php/ijbcp/article/view/4106>
5. Raj C, Panda M, Singh BSTP, Kar BR, Patro N. Prescribing Patterns in the Treatment of Topical Steroid Damaged Face Patients: A Cross-Sectional, Survey-Based Observational Study among Practicing Dermatologists in an Eastern State of India. *Indian Dermatol Online J* [Internet]. 2024 Mar 1 [cited 2025 Dec 23];15(2):247. Available from: <https://pmc.ncbi.nlm.nih.gov/articles/PMC10969254/>
6. Lohiya H, Shinde R, Navande DrS. DERMOSCOPIC FINDINGS SECONDARY TO TOPICAL STEROID APPLICATION OVER FACE: A CROSS SECTIONAL STUDY. *Journal of Population Therapeutics and Clinical Pharmacology* [Internet]. 2025 Feb 22 [cited 2025 Dec 23];32(1):1266–71. Available from: <https://www.jptcp.com/index.php/jptcp/article/view/9399>
7. Ankad BS, Anusha HL, Raghuveer C, Nikam BP, Rangappa M. Skin Changes on the Face Caused by Over-the-counter Cosmetic Creams: An Observational Study of Clinical and Dermoscopy Features. *Skin Changes on the Face Caused by Over-the-counter Cosmetic Creams: An Observational Study of Clinical and Dermoscopy Features* [Internet]. 2023 Jan 10 [cited 2025 Dec 23];16(1):13–9. Available from: <https://ijopp.org/article/982>
8. Jakhar D, Kaur I. Dermoscopy of Topical Steroid Damaged/Dependent Face. *Indian Dermatol Online J* [Internet]. 2018 [cited 2025 Dec 23];9(4):286. Available from: <https://pmc.ncbi.nlm.nih.gov/articles/PMC6042197/>
9. Goel A, Mahendra A, Gupta S. Clinical and Dermoscopic Evaluation of Patients With Topical Steroid Damaged Faces (TSDF). *Cureus* [Internet]. 2024 Nov 28 [cited 2025 Dec 23];16(11). Available from: <https://pubmed.ncbi.nlm.nih.gov/39735096/>
10. Kushwah S, Namdeo C, Bhatia K. Study of clinicodermoscopic features of topical steroid damaged face patients. *International Journal of Research in Dermatology* [Internet]. 2023 Aug 24 [cited 2025 Dec



- 23];9(5):226–32. Available from: <https://www.ijord.com/index.php/ijord/article/view/1710>
11. Meghe S, Saoji V, Singh AL, Kashikar Y, Rusia K, Ramapure R. Topical Steroid Damaged Face - A Dermoscopic Analysis. *J Pharm Bioallied Sci* [Internet]. 2024 Apr 1 [cited 2025 Dec 23];16(Suppl 2):S1510. Available from: <https://pmc.ncbi.nlm.nih.gov/articles/PMC11174278/>
12. Arnold KA, Treister AD, Lio PA. Dupilumab in the management of topical corticosteroid withdrawal in atopic dermatitis: A retrospective case series. *JAAD Case Rep* [Internet]. 2018 Oct 1 [cited 2025 Dec 23];4(9):860–2. Available from: <https://pubmed.ncbi.nlm.nih.gov/30306110/>
13. Mohta A, Sathe NC. Topical Steroid Withdrawal (Red Skin Syndrome). *StatPearls* [Internet]. 2024 May 7 [cited 2025 Dec 23]; Available from: <https://www.ncbi.nlm.nih.gov/books/NBK603718/>
14. Niculet E, Bobeica C, Tatu AL. Glucocorticoid-Induced Skin Atrophy: The Old and the New. *Clin Cosmet Investig Dermatol* [Internet]. 2020 [cited 2025 Dec 23];13:1041. Available from: <https://pmc.ncbi.nlm.nih.gov/articles/PMC7779293/>
15. Goel A, Mahendra A, Gupta S. Clinical and Dermoscopic Evaluation of Patients With Topical Steroid Damaged Faces (TSDF). *Cureus* [Internet]. 2024 Nov 28 [cited 2025 Dec 23];16(11). Available from: <https://pubmed.ncbi.nlm.nih.gov/39735096/>
16. Goel V, aGarwal D, Sachan S, YaDaV V, talwar ankur. Assessment of Topical Steroid-damaged/ Dependent Face Severity Score and its Impact on Quality of Life: A Cross-sectional Study. *Journal of Clinical and Diagnostic Research* [Internet]. 2025 [cited 2025 Dec 23];19(3):7–13. Available from: www.jcdr.net