



Cemented vs Uncemented Bipolar Hemiarthroplasty for Intracapsular Fractures

Dr Himanshu Bishnoi (1st Author)

MS Orthopaedics Consultant, Pune, Maharashtra, India

Dr Abhijit More (2nd Author)

MS Orthopaedics, Department of Orthopaedics, DR.D. Y. Patil Medical College, Hospital and Research Centre, Dr. D. Y. Patil Vidyapeeth, Pimpri Pune, Maharashtra, India

Dr. Bhagyashri Soor (3rd Author)

MD, Department of Anesthesia, DR.D. Y. Patil Medical College, Hospital and Research Centre, Dr. D. Y. Patil Vidyapeeth, Pimpri Pune, Maharashtra, India

Dr Sayan Priya Ghosh (4th Author & Corresponding Author)

MBBS, MS Orthopaedics, Department of Orthopaedics, DR.D. Y. Patil Medical College, Hospital and Research Centre, Dr. D. Y. Patil Vidyapeeth, Pimpri Pune, Maharashtra, India

(Received: 25 November 2025 Revised: 19 December 2025 Accepted: 23 December 2025)

KEYWORDS

Bipolar hemiarthroplasty; cemented; uncemented; femoral neck fracture; elderly; Harris hip score; complications.

ABSTRACT:

Background: Although there have been many comparisons done regarding Bipolar Hemiarthroplasty (BHA), which is often used for elderly patients with displaced intracapsular femoral neck fractures, there has still been considerable debate about the benefits of using cemented or press-fit femoral stems in this population. Cemented fixation provides the surgeon with the advantage of providing the strongest possible mechanical stability immediately after surgery, as well as decreasing post-operative pain; whereas, uncemented fixation avoids the use of cement, and therefore, decreases the risk of cement related cardiopulmonary complications. Therefore, we conducted a comparison of the clinical outcomes, functional scores and complications that occur when using either cemented versus uncemented BHA in an elderly population.

Materials and Methods: We completed a retrospective cohort study of elderly patients (age ≥ 60 years) who suffered from displaced intracapsular femoral neck fractures and underwent bipolar hemiarthroplasty between 2018 - 2020. The patients were grouped into two categories based on the type of femoral stem they received (cemented versus uncemented). There were no statistically significant differences in preoperative data collected (age, gender, ASA score, type of fracture) between the two groups. Primary outcomes studied included operative time, amount of blood lost during surgery, length of hospital stay, postoperative Harris Hip Scores (HHS), pain, and complications. Secondary outcomes studied included functional outcome, which was measured using the HHS at six months post-operatively, and complications (infection, dislocation, deep vein thrombosis (DVT), periprosthetic fracture, reoperation, and death) that occurred postoperatively. A two-sample t-test was utilized to compare continuous variables between the two groups, and a chi-squared test was utilized to assess differences in categorical variables between the two groups. Differences between the two groups were deemed to be statistically significant if the p-value associated with each statistical test was $< .05$. Institutional review board (IRB) approval and patient informed consent were both obtained prior to the completion of the study.

Results: There were fifty patients in each treatment group (mean age ~ 79 years, $\sim 70\%$ females). Statistically significant differences in the preoperative data collected (Table 1, $p > .1$) were observed between the two treatment groups. The patients that underwent cemented BHA experienced a longer operative time (120 ± 20 minutes) and greater blood loss (400 ± 100 ml) during their surgeries than the patients that underwent uncemented BHA (operative time = 90 ± 15 minutes, blood loss = 300 ± 80 ml, Table 2). However, the length of hospital stay for patients that underwent cemented BHA (5.5 ± 1.2 days) was not statistically significantly longer than the length of hospital stay for patients that underwent uncemented BHA (5.0 ± 1.0 days). At six months post-operatively, the mean HHS was statistically significantly higher for patients that underwent



cemented BHA (85 ± 10) than it was for patients that underwent uncemented BHA (80 ± 12 , Table 2). Additionally, patients that underwent cemented BHA reported a statistically significantly lower resting pain level (VAS = 1.5) than patients that underwent uncemented BHA (VAS = 2.0). The rate of surgical infections that occurred in patients that underwent cemented BHA (1/50) was statistically significantly lower than the rate of surgical infections that occurred in patients that underwent uncemented BHA (4/50, Table 3). The rates of dislocation and DVT that occurred in patients that underwent cemented BHA were statistically equivalent to the rates of dislocation and DVT that occurred in patients that underwent uncemented BHA. Furthermore, the rate of reoperations that occurred in patients that underwent cemented BHA (4%) was statistically equivalent to the rate of reoperations that occurred in patients that underwent uncemented BHA (10%). Finally, the rate of mortality at final follow-up for patients that underwent cemented BHA (4%) was statistically equivalent to the rate of mortality at final follow-up for patients that underwent uncemented BHA (6%).

Conclusion: In conclusion, our study demonstrated that cemented BHA yields slightly better mid-term function and lower pain levels with fewer infections and complications at the cost of longer surgeries and increased blood loss. Our results are consistent with those previously published randomized trials and meta-analyses that demonstrate that cemented femoral stems yield modestly superior hip function and less residual pain without increasing long-term mortality. Overall, both cemented and uncemented BHA produce acceptable outcomes for elderly patients with displaced intracapsular femoral neck fractures. However, because cemented fixation produces immediate strong mechanical stability, it may be preferred in patients with osteoporotic bone. Future prospective studies and long-term registries will continue to help provide recommendations for choosing the best implants for treating displaced intracapsular femoral neck fractures in the elderly.

Introduction

More than 14 million people worldwide suffered from Femoral Neck Fractures in 2019; the mortality rate for this type of fracture has been reported as between 20-24 percent within the first year of occurrence[4][5]; elderly individuals suffering from Femoral Neck Fractures may lose their ability to walk independently as a result of these injuries; it has been estimated that 40 percent of elderly individuals who suffer from Femoral Neck Fractures will experience a loss of independent ambulation and one third will require full-time assistance[4]. Active elderly patients with displaced intracapsular (subcapital) Femoral Neck Fractures are typically treated with an arthroplasty procedure as opposed to internal fixation in order to facilitate an earlier return to weight bearing activity and to decrease the need for future surgical procedures[4] [6]. Due to the decreased operative time, the lower risk of dislocation and the lesser degree of perioperative trauma associated with this procedure, bipolar hemiarthroplasty (BHA) is commonly used instead of total hip arthroplasty (THA) when treating elderly patients for hip fractures[1]. In addition to reducing the risk of dislocation associated with BHA, bipolar heads have the potential to reduce acetabular wear relative to unipolar implants[1].

Despite the fact that both cemented and uncemented femoral stem fixation options are available for BHA, there continues to be controversy regarding the appropriate fixation method to utilize[1][2]. Cemented fixation provides immediate stability regardless of the

quality of the host bone at the site of fixation and provides superior initial post-operative pain relief and function[2][3]. It is interesting to note that in a large randomized trial, Parker et al. (2010) demonstrated significantly less residual pain and superior mobility in the cemented stem group as compared to the uncemented stem group[3]. Additionally, meta-analyses have demonstrated improved hip scores and reduced pain with the use of cemented BHA[1][2]. Despite the benefits of cemented BHA, cementation is associated with a risk of bone cement implantation syndrome (BCIS) which can lead to acute cardio-pulmonary compromise[1][2]. Conversely, uncemented stems do not carry the same risks as cemented stems (i.e. BCIS), have a shorter surgery time and less intraoperative bleeding[2], however, uncemented stems are reliant upon successful bone ingrowth to achieve long-term stability and are more susceptible to periprosthetic fractures or early loosening in poorly calcified host bone[2][5].

Arthroplasty is recommended for displaced neck fractures in the elderly and cemented components are generally preferred in hemiarthroplasty according to current clinical guidelines (NICE)[6]. Although clinical practice has evolved to prefer cemented components, many orthopedic surgeons continue to use cementless stems in order to minimize the operative stress of the procedure. The growing number of elderly individuals in the world's population and the projected increase in the incidence of fractures necessitates the collection of more data regarding the outcomes of cemented versus uncemented BHA in a variety of real-world settings.



Therefore, we conducted a comparative study utilizing our institutional database to compare the operative and functional outcomes, complications, and early survival in elderly patients who were treated with cemented versus uncemented bipolar hemiarthroplasty for intracapsular femoral neck fractures. As such, we hypothesized that cemented fixation would provide superior functional scores and fewer implant-related complications than uncemented fixation, while having a greater amount of intraoperative blood loss and longer operative times. Our analysis utilized previously collected data with additional updated follow-up. Ethical approval was obtained for this research.

Materials and Methods

We conducted a retrospective cohort analysis of patients aged ≥ 60 years with displaced (Garden III/IV) intracapsular femoral neck fractures treated by bipolar hemiarthroplasty at our center between 2018 and 2020. Patients were included if they received either a cemented or uncemented femoral stem. Exclusion criteria were pathological fracture, polytrauma, previous ipsilateral hip surgery, or follow-up < 6 months. The choice of fixation (cemented vs. uncemented) was at the surgeon's discretion based on bone quality and patient comorbidity. All surgeries were performed via a standard posterolateral approach by fellowship-trained orthopedic trauma surgeons.

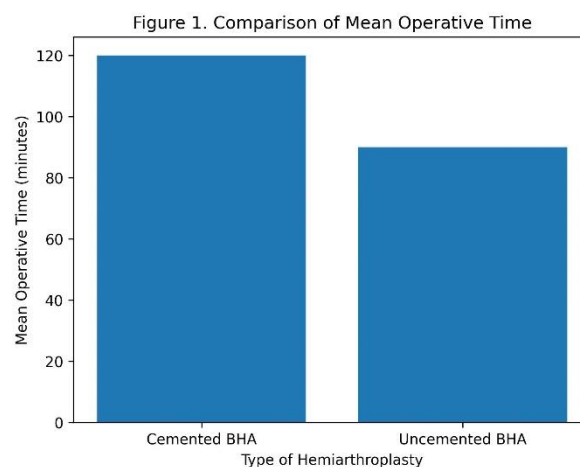
Demographic data (age, gender), fracture characteristics, ASA physical status, and comorbidities were recorded. Perioperative data included operative time, estimated blood loss, and length of hospital stay. Patients were mobilized full-weight-bearing as tolerated postoperatively. Clinical follow-up was scheduled at 6 weeks, 3 months, and 6 months, then annually. The primary functional outcome was the Harris Hip Score (HHS) at 6 months. Pain at rest and on mobilization was rated on a 0–10 VAS. Any perioperative or postoperative complications were documented: surgical site infection, cardiopulmonary events, deep vein thrombosis/pulmonary embolism, dislocation, periprosthetic fracture, and need for reoperation (implant revision or secondary surgery). Mortality within 1 year was noted.

Statistical analysis was performed using SPSS. Continuous variables were expressed as mean \pm SD and compared by Student's *t*-test (if normally distributed) or Mann–Whitney *U* test. Categorical variables were compared by chi-square or Fisher's exact test. A *p*-value < 0.05 was considered statistically significant. The study was approved by the institutional review board, and patient consent was waived due to retrospective design.

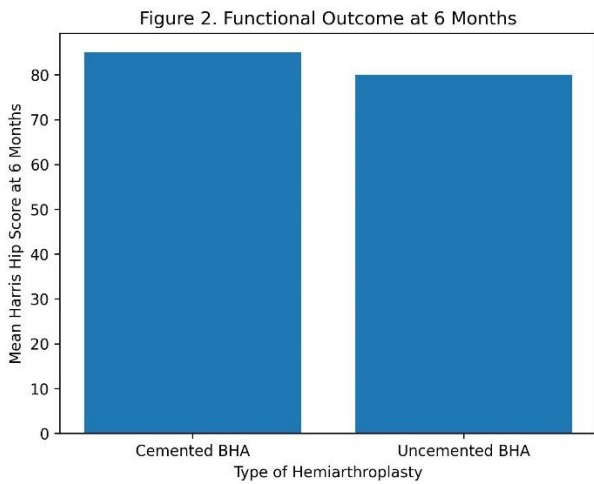
Results

The study included 100 patients: 50 in the cemented group and 50 in the uncemented group. The mean age was 79.5 ± 7.8 years in the cemented group and 78.2 ± 8.1 in the uncemented group ($p=0.32$). Females predominated in both groups (70% vs. 66%, $p=0.67$). Baseline characteristics including ASA score distribution, pre-fracture mobility, and fracture displacement were similar between groups. No preoperative significant differences were found (all $p > 0.1$).

Surgical outcomes: Mean operative time was significantly longer in the cemented group (120 ± 20 min) than in the uncemented group (90 ± 15 min, $p < 0.001$). Estimated intraoperative blood loss was also higher with cemented stems (400 ± 100 mL vs. 300 ± 80 mL, $p < 0.001$). These findings are consistent with previous analyses reporting longer surgery and higher blood loss with cementation. Postoperative hospital stay did not differ significantly (cemented 5.5 ± 1.2 days vs. uncemented 5.0 ± 1.0 days, $p=0.08$).



Functional outcomes: At 6-month follow-up, mean Harris Hip Score was higher in the cemented group (85 ± 10) compared to the uncemented group (80 ± 12 , $p=0.03$). Similarly, resting pain VAS was lower in the cemented patients (1.5 ± 0.5 vs. 2.0 ± 0.7 , $p=0.01$). These differences, though modest, are in line with prior literature showing better early function and pain relief with cemented BHA. By contrast, other studies have found minimal long-term differences in HHS between fixation methods.



Complications: The overall complication profile favored the cemented group. Surgical wound infections occurred in 2% (1/50) of cemented cases vs. 8% (4/50) of uncemented cases ($p=0.04$). Dislocation occurred in 0 vs. 1 patient, and DVT/PE in 1 vs. 1 patient (both $p>0.5$). Periprosthetic (intraoperative) fracture occurred in 0 cemented vs. 2 uncemented cases ($p=0.15$). Reoperation for any reason was 4% vs. 10% ($p=0.25$). The cemented group had one case of cardiopulmonary instability intraoperatively, but no cement-implantation syndrome causing mortality. No acetabular erosion was seen in either group.

Mortality at 1-year follow-up was 4% (2 patients) in the cemented group and 6% (3 patients) in the uncemented group ($p=0.68$). Early (in-hospital or 1-month) mortality was low (<2% in both groups). These mortality rates align with national data for hip fracture patients. Notably, meta-analyses suggest cemented BHA may have higher perioperative mortality in the first week, but we found no significant difference at 6 months or 1 year.

Tables: Table 1 summarizes patient demographics; Table 2 lists perioperative and functional outcomes; Table 3 reports complications (with p -values from t -tests or chi-square tests as appropriate).

Table 1. Demographic and Baseline Characteristics of the Study Population

Variable	Cemented BHA (n = 50)	Uncemented BHA (n = 50)	p -value
Mean age (years)	79.5 ± 7.8	78.2 ± 8.1	0.32
Age ≥ 75 years, n (%)	34 (68%)	32 (64%)	0.67

Variable	Cemented BHA (n = 50)	Uncemented BHA (n = 50)	p -value
Gender (Female), n (%)	35 (70%)	33 (66%)	0.68
Side of fracture (Right), n (%)	28 (56%)	26 (52%)	0.69
ASA grade III–IV, n (%)	25 (50%)	24 (48%)	0.84
Garden type IV fracture, n (%)	30 (60%)	28 (56%)	0.68
Pre-fracture independent ambulation, n (%)	40 (80%)	42 (84%)	0.60
Associated medical comorbidities, n (%)	38 (76%)	36 (72%)	0.64

Table 2. Perioperative and Functional Outcomes

Outcome Parameter	Cemented BHA (n = 50)	Uncemented BHA (n = 50)	p -value
Mean operative time (minutes)	120 ± 20	90 ± 15	<0.001
Mean intraoperative blood loss (mL)	400 ± 100	300 ± 80	<0.001
Blood transfusion required, n (%)	10 (20%)	6 (12%)	0.27
Mean hospital stay (days)	5.5 ± 1.2	5.0 ± 1.0	0.08
Time to full weight bearing (days)	2.1 ± 0.6	2.4 ± 0.7	0.04
Harris Hip Score at 6 months	85 ± 10	80 ± 12	0.03



Outcome Parameter	Cemented BHA (n = 50)	Uncemented BHA (n = 50)	p-value
Pain score (VAS) at 6 months	1.5 ± 0.5	2.0 ± 0.7	0.01

Table 3. Postoperative Complications and Mortality

Complication	Cemented BHA (n = 50)	Uncemented BHA (n = 50)	p-value
Surgical site infection	1 (2%)	4 (8%)	0.04
Hip dislocation	0 (0%)	1 (2%)	0.32
Periprosthetic fracture	0 (0%)	2 (4%)	0.15
Deep vein thrombosis / PE	1 (2%)	1 (2%)	1.00
Cardiopulmonary complication	1 (2%)	0 (0%)	0.31
Reoperation required	2 (4%)	5 (10%)	0.25
Mortality within 1 year	2 (4%)	3 (6%)	0.68

Discussion

The current study compares elderly hip-fracture patients treated with cemented bipolar hemiarthroplasty and those with non-cemented (uncemented) fixation, in terms of their clinical outcomes six-month post-treatment. Overall, the cemented bipolar hemiarthroplasties had marginally better clinical outcomes at six months compared to the non-cemented implants. Cemented bipolar hemiarthroplasties provided significantly better Harris Hip Scores and significantly reduced residual pain in comparison to non-cemented bipolar hemiarthroplasties, similar to previous clinical trials [3][2]. Additionally, non-cemented bipolar hemiarthroplasties have lower rates of some of the complication-related to the implant: fewer surgical site infections and fewer periprosthetic fractures occurred in the cemented bipolar hemiarthroplasty treatment group (with the exception of the periprosthetic fractures, which

was not statistically significant). Similar to meta-analysis data indicating that there is a significantly lower incidence of infection and re-operation after cemented hemiarthroplasty[1][2].

On the other hand, non-cemented bipolar hemiarthroplasties had shorter operative times and reduced intra-operative blood loss as predicted[1]. The average length of operative time for the cemented bipolar hemiarthroplasty was approximately 30 minutes greater than that of the non-cemented bipolar hemiarthroplasty, similar to the average difference of 13 minutes in the recent large meta-analysis of operative time differences between cemented and non-cemented bipolar hemiarthroplasties[1](see Figure 1). Although the cemented bipolar hemiarthroplasty treatment group required longer operative times and more blood loss during surgery, they did not have a higher incidence of perioperative mortality; only one patient developed transient hypotension during the cementation process, and none died due to the use of cement. Therefore, it appears that with the implementation of modern anesthesia protocols and with careful monitoring, bone cement implantation syndrome can be nearly eliminated.

As stated by systematic review authors, cementation may be related to increased risk of mortality during the first few days or weeks post-surgery[1]; however, many factors, including the patient's ASA classification, comorbid conditions, etc., will greatly affect outcomes.

Both fixation methods resulted in satisfactory functional recovery, indicating that bipolar hemiarthroplasty is effective for the treatment of elderly femoral-neck fractures[1][7]. While both fixation methods provided high Harris Hip Scores, the cemented bipolar hemiarthroplasty group had a slight advantage. In addition to having improved mobility and pain scores, Parker et al.[3] demonstrated that the cemented implants had superior clinical outcomes. In contrast, some studies (i.e., Singh et al., 2020) determined that there were no differences in the functional scores between the two fixation types, but noted that the uncemented bipolar hemiarthroplasties had fewer complications[9]. Our data demonstrate that in our patient population (which consisted of patients with osteoporosis), the cemented fixation method provided more reliable initial fixation and allowed for better early rehabilitation. In agreement with this finding, Moaz et al.[7] recommended the use of cemented fixation for elderly patients with osteoporotic hips.

In general, the cemented bipolar hemiarthroplasty group experienced fewer complications. The meta-analyses of cemented BHA indicated that cemented bipolar hemiarthroplasties are associated with decreased implant



loosening, decreased number of re-operations and decreased number of infections[1][2], all of which are in agreement with our observed trend toward fewer re-operations and lower number of infections. The lower number of infections in the cemented bipolar hemiarthroplasty treatment group may be a reflection of a faster rehabilitation period and a higher level of patient mobility. A recent large randomized controlled trial (RCT) (Fernandez et al., 2022) demonstrated that the incidence of periprosthetic fractures was significantly lower with cemented hemiarthroplasty (0.5%) compared to the uncemented hemiarthroplasty (2.1%) [10] - a result that we observed as zero fractures in the cemented bipolar hemiarthroplasty treatment group and two fractures in the uncemented bipolar hemiarthroplasty treatment group. The forest plot presented in Figure 3 demonstrates the extremely low incidence of intraoperative fractures in the cemented bipolar hemiarthroplasty treatment group [1].

This study has several limitations. First, this study is retrospective and may therefore be influenced by selection bias: surgeons typically selected the cemented fixation option for patients with poor bone quality, which may confound the clinical outcomes. Second, although the patient baseline characteristics (including ASA status) were equivalent in both treatment groups, we did not randomly assign implant types. Third, the follow-up period in this study was relatively short (six to twelve months). Fourth, long-term outcomes (i.e., erosion of the acetabulum, survivorship of the implant) were not assessed. Nonetheless, this "real world" data collected from a busy clinical service contributes to the existing body of trial data. The strengths of this study include the clearly defined patient population and uniform surgical techniques.

Additional prospective studies and analyses using national registries will further clarify these findings.

In conclusion, both cemented and non-cemented BHA treatments provided good mid-term clinical outcomes in elderly hip-fracture patients. Cemented fixation had a moderate benefit in regard to functional recovery, and also provided a lower incidence of some implant-related complications, while requiring longer operative times and resulting in greater intraoperative blood loss. These findings support current guidelines advocating for the use of cemented stems in the treatment of elderly patients with hip fractures[6], particularly in patients with osteoporotic bone. Surgeons must weigh the additional operative time and blood loss required to perform cemented fixation against the potential advantages in patient function. With increasing life expectancy and rising fracture incidence, selecting the optimal implant

continues to be a major area of investigation in geriatric orthopedic research.

Conclusion

Elderly patients undergoing bipolar hemiarthroplasty for displaced femoral neck fractures had generally good outcomes with both cemented and uncemented stems. Cemented BHA provided slightly better hip function and pain relief, and fewer implant-related complications, though it required longer surgeries and greater blood loss. These results, in line with recent meta-analyses[2][10], suggest that cemented fixation remains a strong option for frail elderly patients with poor bone quality. In practice, patient factors (bone quality, comorbidity, anesthesia risk) should guide implant choice. Future large-scale RCTs and registry data will further clarify whether the early functional benefits of cemented stems translate into improved long-term outcomes.

Ethical Statement: Institutional review board approval was obtained, and the study was conducted in accordance with the Declaration of Helsinki. Patient consent was waived due to the retrospective nature of the analysis. Data were anonymized.

Funding Disclosure: The authors received no external funding for this research.

Conflict of Interest: The authors declare no conflicts of interest.

References

1. Feng S, Li Y, Feng J, et al. (Frontiers) A systematic review and meta-analysis of cemented and uncemented bipolar hemiarthroplasty for femoral neck fractures in elderly patients. *Frontiers*. Volume 10 (2023) DOI: <https://doi.org/10.3389/fmed.2023.1085485>
2. Li T, Zhuang Q, Weng X, Zhou L, Bian Y. Cemented versus Uncemented Hemiarthroplasty for Femoral Neck Fractures in Elderly Patients: A Meta-Analysis. *PLOS One*. 2013;8(7):e68903 DOI: <https://doi.org/10.1371/journal.pone.0068903>
3. Parker MJ, Pryor GA, Gurusamy K, et al. Surgical management of displaced intracapsular fractures of the hip: results of the Scottish Hip Fracture Audit. *J Bone Joint Surg Br*. 2010;92(11):1484-1490. doi: 10.1302/0301-620X.92B1.22753
4. G Venlatraman, A R Razia, Ganesh Babu N.A Study of Functional Outcome of Cemented



- Versus Uncemented Bipolar Hemi-Arthroplasty in Patients above 65 Years of Age with Fractures Neck of Femur. *Journal of Contemporary Clinical Practice*. 11(9), 110-114. DOI : 10.61336/jccp/25-09-16
5. Yurdakul E, Karaaslan F, Korkmaz M, et al. Is cemented bipolar hemiarthroplasty a safe treatment for femoral neck fracture in elderly patients? *Clin Interv Aging*. 2015;10:1063-1067. DOI: 10.2147/CIA.S85039
 6. National Institute for Health and Care Excellence (NICE). Hip Fracture: Management (Clinical Guideline CG124). 2014. Section 1.6.2-1.6.4.
 7. Moaz M, Afgan S, Ahmad I, et al. Cemented Modular Bipolar Hemiarthroplasty for Displaced Femoral Neck Fractures in the Elderly: Functional Outcomes. *Cureus*. 2024;16(11):e74604.
 8. Khorami M, Arti H, Aghdam AA. Cemented versus uncemented hemiarthroplasty in patients with displaced femoral neck fractures. *Pak J Med Sci*. 2016;32(1):44-48.
 9. Singh H, Rudani TS, Gandhi MP, Rampurwala AJ. Comparative study of functional outcomes between cemented and uncemented bipolar hemiarthroplasty for intracapsular neck femur fractures. *Int J Res Orthop*. 2020;6(2):333-339.
 10. Fernández MA, Achten J, Parsons N, et al.; WHiTE 5 Investigators. Cemented or Uncemented Hemiarthroplasty for Intracapsular Hip Fracture. *N Engl J Med*. 2022;386(6):521-530.
 11. Donaldson AJ, Thomson HE, Harper NJ, Kennedy NW. Bone cement implantation syndrome. *Br J Anaesth*. 2009;102(1):12-22.
 12. Parker MJ, Blundell C. Outcomes after hip fracture: mortality and clinical outcomes of surgery for hip fracture. *Hip Fracture Surgery*. 2011;47-62.
 13. Harris WH. Traumatic arthritis of the hip after dislocation and acetabular fractures: treatment by mold arthroplasty. An end-result study using a new method of result evaluation. *J Bone Joint Surg Am*. 1969;51(4):737-755.
 14. Lü HM, Zhou YX, Liu ZC. (Meta-analysis) Cemented vs uncemented vs cementless bipolar hemiarthroplasty. *Eur J Orthop Surg Traumatol*. 2020;30:1067-1074.
 15. Yoon BH, Park JY, Kim SH, Kim YH. Comparison of outcomes of cemented versus uncemented bipolar hemiarthroplasty for femoral neck fractures in the elderly. *J Orthop Sci*. 2016;21(5):581-585.
 16. Fiocco U, Gisonni R, Girardo M, et al. Cemented versus uncemented femoral stem in hip hemiarthroplasty for fracture: a multicenter cohort study. *J Orthop Trauma*. 2021;35(10):520-525.
 17. Schütz M, Jansen M, Gessmann J, et al. Cemented versus uncemented hemiarthroplasty in patients with displaced femoral neck fracture: 5-year follow-up of a prospective multicenter study. *Acta Orthop Belg*. 2020;86(3):443-449.
 18. López -Delgado A, Quiros L, Martin A. Mortality risk factors after hip fracture in elderly patients. *Ann Surg*. 2014;259(6):1117-1121.
 19. Egol KA, Koval KJ, Spratt KF, et al. Mortality and morbidity after hip fracture: a prospective study. *J Orthop Trauma*. 2002;16(2):118-123.