



Partial Ossicular Reconstruction Prosthesis and Total Ossicular Reconstruction Prosthesis – A Review on its Postoperative & Functional Outcome on Hearing

M K Rajasekar ¹, M.shanmugapriya ²

¹Professor and Head of the Department, Department of ENT, Sree Balaji Medical College and Hospital, Chrompet

²Post Graduate Student, Department of ENT, Sree Balaji Medical College and Hospital, Chrompet

(Received: 02 September 2023

Revised: 14 October

Accepted: 07 November)

Keywords:

Ossicular
Reconstruction, Partial
Prosthesis, Hearing
Impairment.

Abstract

Introduction-According to the World Health Organization, 63 million people in India have significant hearing impairment. Reports of NSSO survey in the year 2001 suggest that there are 291 persons per one lakh population suffering from severe to profound hearing loss. **Methodology**- Prospective study conducted among 32 patients came to the outpatient department with complaints of ear discharge and hard of hearing. An informed consent was obtained from all patients following which all our patients were operated under general anaesthesia. A William Wilde postaural incision is made and extended up and temporalis fascia graft was harvested. The incision was deepened and then a T shaped incision was made and periosteum was elevated. Spine of Henle was identified. A meatotomy was done and pinna retracted forwards. Tympanomeatal flap was elevated. Bone work was started in the MacEwan's triangle and the mastoid antrum reached which is usually located at a distance of 1-1.5cm from the mastoid cortex. **Results**- The results were analyzed after following up the patients every week for the first month postoperatively followed by monthly for the next 2 months postoperatively. The collected data were analysed with SPSS software 23.0 Version. There was a male predominance in the study group. In majority of cases the prosthesis that was used was PORP. **Conclusion**-Ossiculoplasty gives better results when compared to cases where ossiculoplasty isn't done. Ossiculoplasty should always be done in patients with conductive hearing loss which is secondary to ossicular pathology.

Introduction

According to the World Health Organization, 63 million people in India have significant hearing impairment. Reports of NSSO survey in the year 2001 suggest that there are 291 persons per one lakh population suffering from severe to profound hearing loss.¹

Even though the first ossiculoplasties date back to the 1950s, the first ossiculoplasty using a titanium prosthesis was realized by Stupp in 1993.² Since then, titanium has become a privileged material for use in ossiculoplasty. Some of its main advantages include an excellent biocompatibility, lightweight, and a good rigidity.^{1,7} During surgery, it is necessary to interpose cartilage between the TM and the prosthesis to minimize the risk of prosthesis extrusion. With this procedure, the extrusion risk is evaluated, according to initial studies,

between 1% and 2% with a follow-up of up to 3 years. Audiometric results seem to be equivalent or slightly superior to those obtained with bioactive materials such as hydroxyapatite. Operative success with ossiculoplasty is defined as an air-bone gap (ABG) closure inferior to 20 dB. Operative success after total reconstruction with a total titanium ossicular prosthesis is between 40% and 60% according to some reports.^{3,4} With the development of ear microsurgery techniques for Chronic Suppurative Otitis Media (CSOM), the treatment of CSOM has improved from just preventing complications to a focus on the improvement and restoration of hearing. With the ability to reconstruct ossicles, the treatment of CSOM has made great progress over the past decades. The primary objectives of tympanoplasty are



infection control, hearing rehabilitation using ossicular reconstruction and closure of the tympanic membrane using grafting techniques.^{4,5} Ossiculoplasty may be defined as restoring the hearing mechanism between the tympanic membrane and the oval window by re-establishing a functioning ossicular chain. By doing so, there is a reduction in the air-bone gap postoperatively, thus improving the hearing of the patient.^{6,7}

The aim of the current research was to study the effectiveness of Teflon PORP and TORP in ossicular reconstruction, to study the difference between pre-operative and post-operative pure tone audiogram showing an improvement in hearing, and to study the post-operative graft uptake.

Methodology

Prospective study conducted at Madras Medical College and Rajiv Gandhi Government General hospital, Chennai 003 between October 2021 and September 2023. The study population included patients who came to the outpatient department and were diagnosed with CSOM clinically. A total of 32 patients came to the outpatient department with complaints of ear discharge and hard of hearing. After a thorough history and examination, patients were enrolled in this study. After obtaining the institutional ethics committee approval, the study was conducted among individuals with age between 20 and 50 years, chronic otitis media with ossicular erosion, Chronic otitis media with conductive hearing loss, traumatic ossicular discontinuity and of both genders (male and female). At the same time individuals between below 20yrs of age and above 50yrs, with chronic otitis media with impending or overt complications and with chronic otitis media with profound sensorineural hearing loss were excluded from the study. A detailed history was collected from all the patients and a thorough physical examination of the ear was performed. HRCT temporal bone and pure tone audiogram were also done. The pure tone average and air-bone gap were calculated preoperatively. Patients were then prepared for surgery and ossicular status was assessed. If the ossicles were eroded, either a TORP or a PORP was used for ossicular reconstruction depending on the ossicles eroded. If the incus alone was eroded, a PORP was introduced and if the incus and suprastructure

of stapes were eroded with or without erosion of malleus, a TORP was used. A postoperative pure tone audiogram was then done to calculate the pure tone average and the air-bone gap. This was compared to the preoperative audiogram.

Once the diagnosis was made, appropriate treatment in the form of conservative management for ear discharge after ear discharge for pus culture and sensitivity was started if the patients had complaints of ear discharge. Routine blood investigations such as complete blood count, renal function test, random blood sugar, chest X-ray and electrocardiogram were done for anaesthetic purpose. Visual analogue scale was used to assess the severity of symptoms. Ear discharge- The characteristics of ear discharge were assessed. If scanty, continuous, purulent, foul smelling and blood stained ear discharge – indicates chronic otitis media with cholesteatoma. If profuse, intermittent, mucoid or mucopurulent – indicates tubotympanic disease. The duration of the discharge and period of dryness tells us whether the ear is-Active, Quiescent (dry for a period of less than 3 months), Inactive (dry for a period of 3 or more months). Preoperatively, a pure tone audiogram was done which gave a qualitative and quantitative analysis of hearing. A pure tone average was taken to assess the degree of hearing loss at frequencies of 500Hz, 1000Hz and 2000Hz as they compare to the speech frequency.

An informed consent was obtained from all patients following which all our patients were operated under general anaesthesia. A William Wilde postaural incision is made and extended up and temporalis fascia graft was harvested. The incision was deepened and then a T shaped incision was made and periosteum was elevated. Spine of Henle was identified. A meatotomy was done and pinna retracted forwards. Tympanomeatal flap was elevated. Bone work was started in the MacEwan's triangle and the mastoid antrum reached which is usually located at a distance of 1-1.5cm from the mastoid cortex.

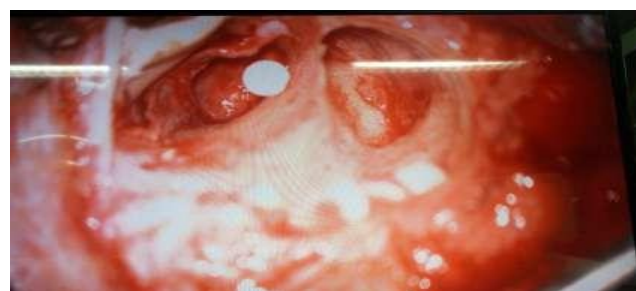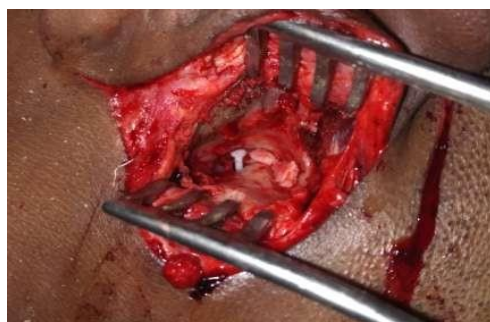The following were analysed -Extent of the disease determining whether to do an intact canal wall or canal wall down procedure, the ossicular status according to Austin's classification., In an intact canal wall procedure, the canal wall is preserved. In canal wall down procedures, the bridge is removed and the ridge is reduced while reducing the anterior



and posterior buttresses, thereby making the mastoid and middle ear into a single cavity. After disease clearance, an ossiculoplasty is done using TORP or PORP depending on the ossicular status. If the incus alone is eroded, PORP is used. If incus and suprastructure is eroded, a TORP is used. The TORP

and PORP have to be altered for length before being used. A cartilage cap is then kept between the prosthesis and tympanic membrane. In canal wall down mastoidectomy, conchal cartilage was used and in intact canal wall mastoidectomy, tragal cartilage was harvested.(fig 1 and 2)

Fig 1 and 2



Results

The results were analyzed after following up the patients every week for the first month postoperatively followed by monthly for the next 2 months postoperatively. The collected data were analysed with IBM.SPSS statistics software 23.0 Version. To describe about the data descriptive statistics frequency analysis, percentage analysis were used for categorical variables and the mean & S.D were used for continuous variables. The Shapiro Wilk's test for normality shoed the data were normal hence to find the significant difference between the bivariate samples in Paired groups the Paired sample t-test was used and for Independent groups the Unpaired t test was used. In both the above statistical tools the probability value .05 is considered as significant level.



Table 1 showing distribution of gender among study population

	Frequency	Percent
Female	14	46.7
Male	16	53.3
Total	30	100.0

There was a male predominance in the study group

Table 2 showing distribution study population among diagnosis

Diagnosis	Fre- quency	Percent
Bilateral COM	5	15.6
Left adhesive OM	3	9.4
Left cholesteatoma	3	9.4
Left COM	10	31.3
Right adhesive OM	2	6.3
Right cholesteatoma	2	6.3
Right COM	7	21.9
Total	32	100.0

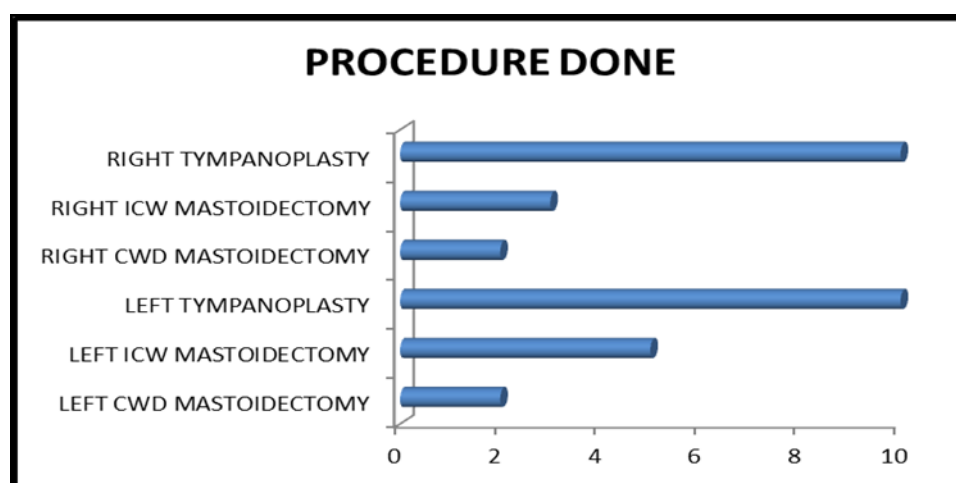


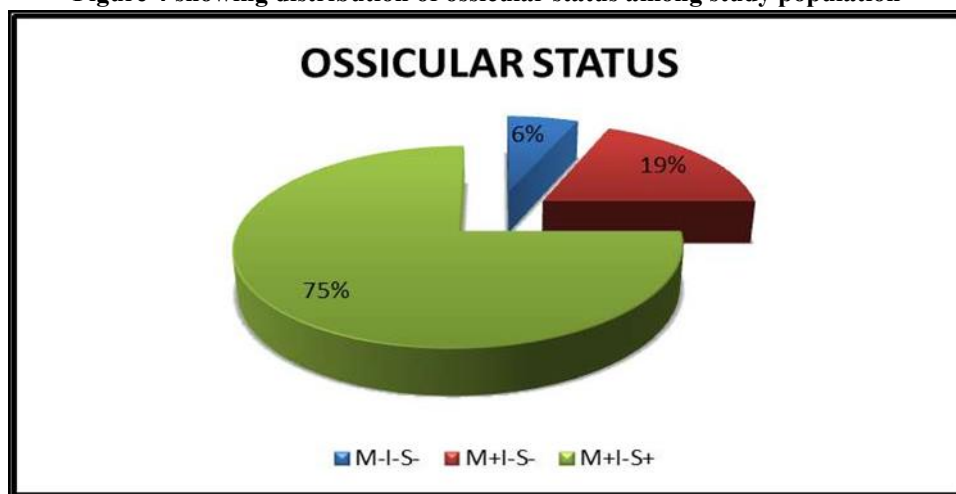
Figure 3 showing distribution study population among diagnosis based on Procedure Done
Majority of the surgeries performed was tympanoplasty

Table 4 showing distribution of prosthesis study population among diagnosis

	Frequency	Percent
PORP	24	75.0
TORP	8	25.0
Total	32	100.0

In majority of cases the prosthesis that was used was PORP

Figure 4 showing distribution of ossicular status among study population



Most common ossicle eroded was the Incus.

Table 5 showing distribution of Pre vs Post Operative PTA among study population

		Levene's Test for Equality of Variances		t-test for Equality of Means						
		F	Sig.	t	df	Sig. (2-tailed)	Mean Difference	Std. Error Difference	95% Confidence Interval of the Difference	
									Lower	Upper
PRE-OP PTA	Equal variances assumed	24.373	.000	-10.540	30	.0005	-19.833	1.882	-23.676	-15.990
	Equal variances not assumed			-6.840	7.590	.000	-19.833	2.900	-26.583	-13.084
POST- OP PTA	Equal variances assumed	2.581	.119	-5.566	30	.0005	-10.208	1.834	-13.954	-6.463
	Equal variances not assumed			-4.225	8.540	.003	-10.208	2.416	-15.720	-4.697
HEARING GAIN	Equal variances assumed	1.094	.304	-8.645	30	.0005	-9.625	1.113	-11.899	-7.351
	Equal variances not assumed			-7.498	9.815	.000	-9.625	1.284	-12.492	-6.758
DURATION OF	Equal vari	.970	.333	1.375	30	.179	2.625	1.909	-1.274	6.524



ILLNESS	ances assumed									
	Equal vari ances not assumed			1.998	27.994	.056	2.625	1.314	-.066	5.316

Comparison of the pure tone audiometry was done and on comparison of pre and post-operative pure tone average, there was a hearing gain that was significant ($P = .0005$). Comparison of the pure tone audiometry was done and on comparison of pre and post-operative pure tone average for PORP, there was a hearing gain that was significant ($P = .0005$). Comparison of the pure tone audiometry was done and on comparison of pre and post-operative pure tone average for TORP, there was a hearing gain that was significant ($P = .0005$).

Discussion

The present study was undertaken to estimate the Partial Ossicular Reconstruction Prosthesis and Total Ossicular Reconstruction Prosthesis 32 consecutive cases. The age group of the study population was 20 to 50 years. Out of these 15 were between 20-30 years of age, 7 were between 30-40 years and 8 were above 40 years of age. And 14 of them were female patients and 18 were male patients. Out of the 32 cases 24 underwent PORP ossiculoplasty while 8 underwent TORP ossiculoplasty, which was found in contrast to the research conducted by Brian A. Neff, et al. (2003)⁸.

The higher rate of prosthesis fixation in the TORP-F group is not statistically significant because of the short distance between the fallopian canal and the promontory at the level of the oval window niche resulting in friction between the bone and the titanium ring holding the legs of the TORP and this is not due to the fat interposition. This can be countered by a slight curettage to enlarge the niche of the oval window.⁴

Adult success rates (55% TORP-F versus 38% TORP-S) were comparable with those found in literature (40%-60%).^{8,9} However, pediatric success rates (30% TORP-F versus 15% TORP-S) were inferior to those seen in pediatric TORP literature (51%-80%).^{10,11} There are few studies available in the literature, which are done exclusively with titanium implants on a pediatric population. Michael et al¹² obtained an 80% success rate with a small cohort of 14 patients. Nevoux et al¹³ obtained a 56% success rate with TORP ($n = 116$), with

all procedures being second-look postcholesteatoma surgeries. However, other factors can contribute to a less hearing improvement, such as the postoperative complications, including external auditory canal or mastoid cavity infection, middle ear fibrosis, prosthesis extrusion, TM thickening or retraction, and prosthesis fixation as well. Moreover, more than 50% of our cohort had a diagnosis of cholesteatoma. There is actually a controversy in the literature regarding the aggressiveness of pediatric cholesteatomas when compared with adult cases.⁸ Many authors have published a recurrence of cholesteatomas in the pediatric population which are 2 to 3 times superior than the adult population with the same diagnosis.^{3,5,9} Another study published by Palva et al¹⁴ suggests that pediatric cholesteatomas have a growth pattern that is more aggressive and extensive than in adult population. A more recent study demonstrated that pediatric specimens of cholesteatomas are characterized by an epithelial matrix which is thicker, that they express a higher level of metalloproteinase at the matrix level, and that they have a higher and more exaggerated inflammatory profile demonstrating that these biological factors are in favor of a more aggressive behavior in pediatric cases when compared with adult cases.¹⁵

Conclusion

Ossiculoplasty gives better results when compared to cases where ossiculoplasty isn't done. Ossiculoplasty should always be done in patients with conductive hearing loss which is secondary to ossicular pathology. This can be done at a primary or second sitting. Teflon prosthesis gives an acceptable hearing gain. Teflon is cost effective when compared to other commercially available prosthesis. Teflon is taken up well in the three month follow up period. The only complication recorded was extrusion of the prosthesis which was seen in 1 case. Long term results are awaited.

References

1. Scott-Brown's Otorhinolaryngology, head and



- neck surgery 7th edition pg.966
2. Stupp CH, Stupp HF, Grün D. Replacement of ear ossicles with titanium prostheses. *Laryngorhinootologie*. 1996;75:335–337.
 3. Dalchow CV, Grün D, Stupp HF. Reconstruction of the ossicular chain with titanium implants. *Otolaryngol Head Neck Surg*. 2001;125:628–30.
 4. Zhang LC, Zhang TY, Dai PD, Luo JF. Titanium versus non-titanium prostheses in ossiculoplasty: a meta-analysis. *Acta Otolaryngol*. 2011;131:708–15.
 5. Sade J, Berco E, Buyanover D, Brown M. Ossicular damage in chronic middle ear inflammation. *Acta Otolaryngol*. 1981;92:273–283.
 6. De Vos C, Gersdorff M, Gerard JM. Prognostic factors in ossiculoplasty. *Otol Neurotol*. 2007;28(1):61–7
 7. Fisch U, May J. Tympanoplasty, Mastoidectomy and Stapes Surgery. New York: Thieme; 1994
 8. Glasscock & Shambough *Surgeries of the ear* 6th edition pg. 63 - 68, Pg.489-498
 9. Brian A. Neff; Franklin M. Rizer; Arnold G. Schuring; William H. Lippy (2003). Tympano-Ossiculoplasty Utilizing the Spiggle and Theis Titanium Total Ossicular Replacement Prosthesis. , 113(9), 1525–1529. doi:10.1097/00005537-200309000-00021
 10. Mardassi A, Deveze A, Sanjuan M, et al. Titanium ossicular chain replacement prostheses: prognostic factors and preliminary functional results. *Eur Ann Otorhinolaryngol Head Neck Dis*. 2011;128:53–58.
 11. Quesnel S, Teissier N, Viala P, Couloigner V, Van Den Abbeele T. Long term results of ossiculoplasties with partial and total titanium Vario Kurz prostheses in children. *Int J Pediatr Otorhinolaryngol*. 2010;74:1226–1229.
 12. Preciado DA. Biology of cholesteatoma: special considerations in pediatric patients. *Int J Pediatr Otorhinolaryngol*. 2012;76:319–321.
 13. Michael P, Fong J, Raut V. Kurz titanium prostheses in paediatric ossiculoplasty—short term results. *Int J Pediatr Otorhinolaryngol*. 2008;72:1329–1333.
 14. Nevoux J, Moya-Plana A, Chauvin P, Denoyelle F, Garabedian EN. Total ossiculoplasty in children: predictive factors and long-term follow-up. *Arch Otolaryngol Head Neck Surg*. 2011;137:1240–1246.
 15. Palva A, Karma P, Kärjä J. Cholesteatoma in children. *Arch Otolaryngol*. 1977;103:74–77.
 16. Dornelles Cde C, da Costa SS, Meurer L, Rosito LP, da Silva AR, Alves SL. Comparison of acquired cholesteatoma between pediatric and adult patients. *Eur Arch Otorhinolaryngol*. 266:2009;1553–61.